

SPONTANEOUS CLOSURE OF BILATERAL ORO-ANTRAL COMMUNICATION FORMED AFTER MAXILLARY PARTIAL RESECTION IN “KROKODIL” DRUG RELATED JAW OSTEONECROSIS PATIENT: CASE REPORT

HAKOBYAN K.A.^{1*}, POGHOSYAN YUM.²

¹Department of Maxillofacial Surgery, “Kanakaner-Zeytun” MC, Yerevan, Armenia,

²Department of Maxillofacial Surgery, Faculty of Postgraduate and Continuing Education, Yerevan State Medical University after M. Heratsi, Yerevan, Armenia

Received 11/06/2017; accepted for printing 08/07/2017

ABSTRACT

“Krokodil” is the street name of a drug mixture, which is used as a cheap and easy available substitute for heroin. Drug component of “Krokodil” is desomorphine, which is an opiate. Codeine containing analgesics (“Sedalgin”, “Pentalgin” etc), iodine, soda, red phosphorus (from match boxes), hydrochloric acid, gasoline and similar substances are used for this purpose. Jaw osteonecrosis is a common complication in “Krokodil” drug users. It occurs as alveolar process exposure in oral cavity. Low rate of recurrence is found in patients with drug withdrawal (minimum 1 month prior to surgery) and jaw resection for a minimum of 0.5 cm towards the healthy tissues. No cases of recurrence were seen after surgery on the maxilla. But in 38% of cases after maxillary osteonecrosis treatment an oroantral communication was formed.

We report a case of 40-year old male patient with “Krokodil” drug related osteonecrosis of maxilla. Patient history included 1.5 year of “Krokodil” use, with 5 month drug withdrawal prior to surgery. Patient was HCV positive. Partial exposure of the right maxilla was found during intraoral examination. Whole maxillary alveolar process, hard palate and parts of zygomatic bones were found necrotic, after vestibular and palatal mucoperiosteal flaps elevation. Necrotic bone tissue was resected about 0.5 cm towards the healthy tissues. Nasal cavity floor and bilateral maxillary sinus floor total defects were formed after necrotic bone removal. Intraoral wound was closed by suturing vestibular and palatal mucoperiosteal flaps. Tension-free wound closure was not achieved. Sutures were removed on tenth postoperative day and bilateral maxillary floor defects were found. On two-month postoperative intraoral examination spontaneous closure of bilateral maxillary floor defects were found. Communications between oral cavity and maxillary sinuses were not found.

KEYWORDS: “Krokodil” drug; jaw osteonecrosis; jaw resection; oro-antral communication

INTRODUCTION

“Krokodil” is the street name of a drug mixture, which is used as a cheap and easy available substitute for heroin. Drug component of “Krokodil” is desomorphine, which is an opiate. Besides desomorphine, dihydromorphine-3,6-dideoxy and morphinan-4,5-epoxy-3-ol are also found in this mixture [Alves E et al, 2015]. It is synthesized by drug users. Codeine containing analgesics (“Sedalgin”,

“Pentalgin” etc), iodine, soda, red phosphorus (from match boxes), hydrochloric acid, gasoline and similar substances are used for this purpose. “Krokodil” is widely used over the territory of the former USSR (Russia, Ukraine, Armenia and others). It is used intravenously and many toxic components of the mixture enter the bloodstream [Alves E et al, 2015].

Jaw osteonecrosis is a common complication in “Krokodil” drug users. It occurs as alveolar process exposure in oral cavity (Fig.1) [Malanchuk V et al, 2007; Tymofieiev A and Dakal A, 2010; Medvedev Yu and Basin E, 2012; Hakobyan K, 2013]. The exposed bone is of dim greyish yellowish shade and is usually covered with greyish plaque

ADDRESS FOR CORRESPONDENCE:

Koryun A. Hakobyan
7 Baghyan Street, 3 app., Yerevan 0056, Armenia
Tel. (+374 94) 91-59-24
E-mail: hakobyankoryun@yandex.ru

(Fig.1). Empty dental sockets filled with purulent discharge are also found in such patients. The surrounding mucosa is in pale pink color, rarely hyperemic (Fig.1). Clinically intact teeth are often seen in the necrotic jawbones (Fig.1). Intra- and extraoral fistulas in the affected area are common symptoms of the disease.

Surgery is the main method for the treatment of “Krokodil” drug related jaw osteonecrosis patients [Poghosyan Yu et al, 2014]. Low rate of recurrence is found in patients with drug withdrawal (minimum 1 month prior to surgery) and jaw resection for a minimum of 0.5 cm towards the healthy tissues [Poghosyan Yu et al, 2014]. No cases of recurrence were seen after surgery on the maxilla [Poghosyan Yu et al, 2014]. But in 38% of cases after maxillary osteonecrosis treatment an oroantral communication was formed [Poghosyan Yu et al, 2014].

CASE REPORT

A 40-year-old male was referred to the Department of Oral and Maxillofacial Surgery of “Kanaker-Zeytun” m/c (Yerevan, Armenia) with “Krokodil” drug-related osteonecrosis of maxilla. Partial exposure of the right maxilla was found during intraoral examination (Fig.1). The exposed bone was of dim greyish yellowish shade and was covered with greyish plaque (Fig.1). Empty dental sockets filled with purulent discharge were observed (Fig.1). The surrounding mucosa was pale pink, with hyperemic areas (Fig.1). Teeth on the maxilla were mobile and purulent discharge was found through gingival sulcus.

Radiographically total opacification of both maxillary sinuses and no demarcation were found (Fig.2).

Patient history included 1.5 years of “Krokodil” use, with 5 month drug withdrawal prior to surgery. The patient was HCV positive.

Trigger factor for disease onset was tooth extraction 11 months before surgery.

The patient underwent surgical treatment. Whole maxillary alveolar process, hard palate and parts of zygomatic bones were found necrotic, after vestibular and palatal mucoperiosteal flaps elevation (Fig.3). There was clear demarcation line between vital and non-vital bony structures (Fig.3). Necrotic bone tissue was resected about 0.5 cm towards the healthy tissues. Sinus purulent discharge was found from both maxillary sinuses.

Nasal cavity floor and bilateral maxillary sinus floor total defects were formed after necrotic bone removal (Fig.4).

Intraoral wound was closed by suturing ves-

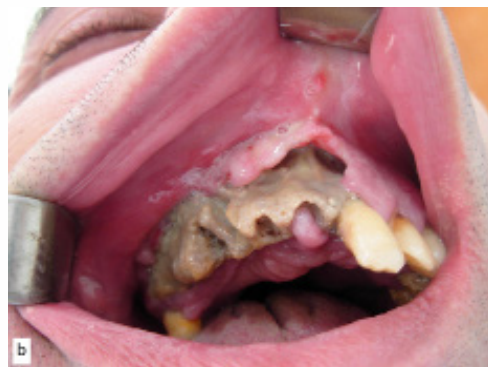

FIGURE 1. Oral cavity view of the patient. Partial exposure of the maxilla

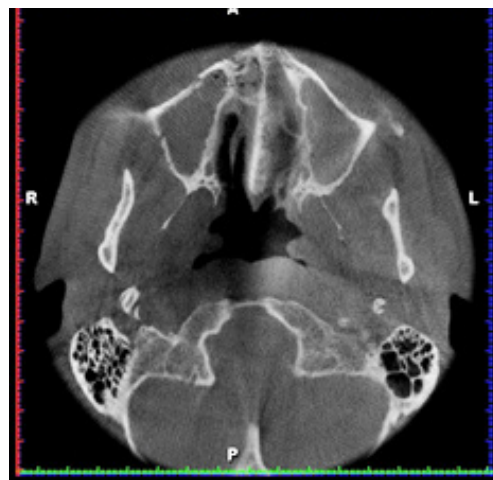

FIGURE 2. Opacification of both maxillary sinuses on CT scan

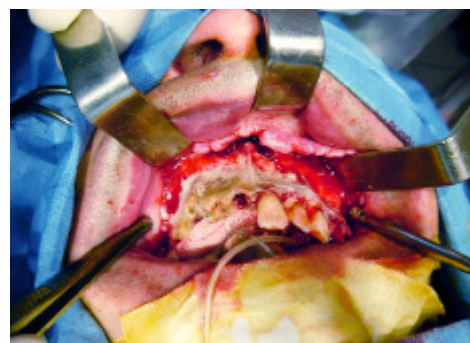


FIGURE 3. Demarcation line between vital and non-vital bony structures

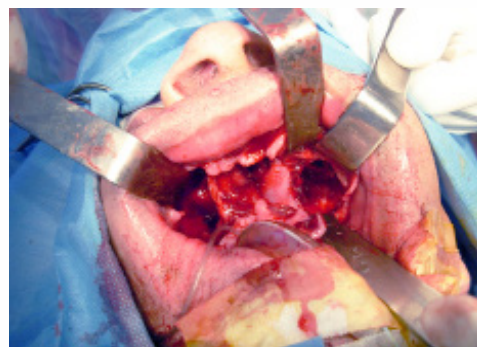


FIGURE 4. Nasal cavity floor and bilateral maxillary sinus floor total defects

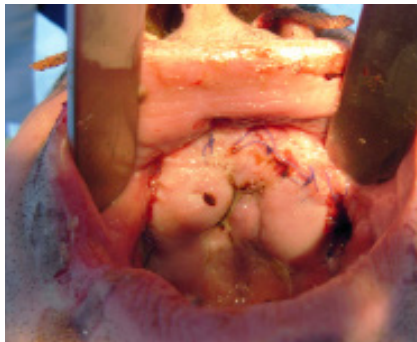


FIGURE 5. Intraoral wound view on first postoperative day

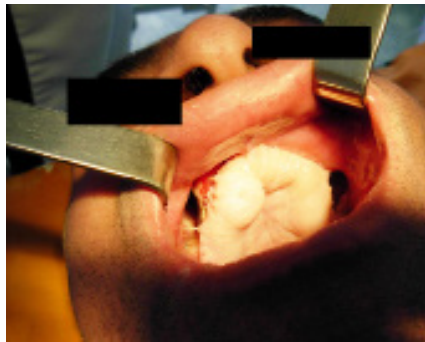

FIGURE 6. One-month postoperative intraoral view of patient. Bilateral oro-antral communications were found

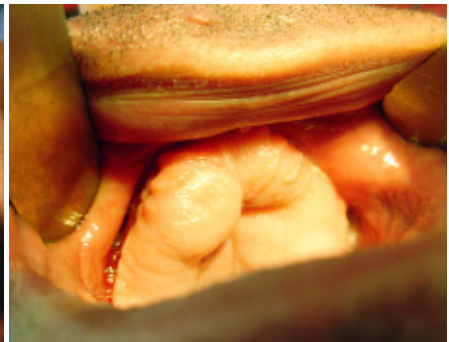

FIGURE 7. Two-month postoperatively. Spontaneous closure of bilateral maxillary floor defects is found

tibular and palatal mucoperiosteal flaps (Fig.5). Tension-free wound closure was not achieved.

Sutures were removed on tenth postoperative day. No exposed bone tissue or purulent discharge was found. Bilateral maxillary floor defects were found during intraoral examination (Fig.6).

On two-month postoperative intraoral examination spontaneous closure of bilateral maxillary floor defects were found (Fig.7). Communications between oral cavity and maxillary sinuses were not found.

DISCUSSION

Surgery is the main method for the treatment of “Krokodil” drug related jaw osteonecrosis patients. Unilateral or bilateral oro-antral communications of different size may form, after resection

or sequestrectomy on distal maxilla. In this case, spontaneous closure of large bilateral oro-antral communication was found two–months postoperatively. In our opinion, this phenomenon was possible due to absence of whole alveolar process of maxilla, bone part of hard palate and parts of zygomatic bones. Large bone defect and soft tissue constricture made possible spontaneous contact of vestibular and palatal soft tissues during postoperative period. Thus, spontaneous closure of large bilateral oro-antral communication was possible.

CONCLUSION

This phenomenon shows that spontaneous closure of bilateral maxillary floor defects is possible after maxillary resection in osteonecrosis patients.

REFERENCES

1. Alves EA, Soares JX, Afonso CM, Grund JP, Agonia AS, Cravo SM, Netto AD, Carvalho F, Dinis-Oliveira RJ. The harmful chemistry behind “krokodil”: street-like synthesis and product analysis. *Forensic Sci Int* 2015; 257:76–82
2. Hakobyan KA. [Clinical picture, diagnosis and treatment of facial bones osteonecrosis at patients who use the drug “krokodil”] [Published in Russian] Autoref Diss Cand Med Sci. Yerevan 2013.
3. Malanchuk VA, Kopchak AV, Brodetsky IS. [Clinical features of jaw osteomyelitis in drug addicted patients][Published in Ukrainian] *Ukrainian Medical Journal*. 2007; 4(60):111–117
4. Medvedev YA, Basin EM. [Phosphorus jaw osteonecrosis] [Published in Russian] *Vrach* 2012; 1:21–25
5. Poghosyan YuM, Hakobyan KA, Poghosyan AY, Avetisyan EK. Surgical treatment of jaw osteonecrosis in “krokodil” drug addicted patients. *Journal of Cranio-Maxillo-Facial Surgery*. 2014; 42:1639–1643
6. Tymofieiev AA, Dakal AV. [Clinical course of purulent inflammatory diseases of the jaws and soft tissues of the maxillofacial area in patients using “Vint” drug] [Published in Russian] *Mod Stomatol*. 2010; 1:96–102