

USE OF FIXED INDIVIDUAL MICRO-IMPLANT SUPPORTED ORTHODONTIC APPLIANCE IN CHILDREN WITH BILATERAL CLEFT LIP AND PALATE

MARGARYAN E.G.¹, MAMEDOV AD.A.², DUDNIK O.V.^{2*}, VOLKOV Y.O.², MAZURINA L.A.²,
ZUBKOV A.V.², ODZHAGGULIEVA G.E.², AKHMETKHANOV S-M.A.², GORLOVA N.V.², GUOPEI M.A.²

¹Department of Therapeutic Dentistry, Institute of Dentistry, I.M. Sechenov First Moscow State Medical University, Moscow, Russia

²Department of Pediatric Dentistry and Orthodontics, I.M. Sechenov First Moscow State Medical University, Moscow, Russia

Received 03.02.2020; accepted for printing 14.07.2020

ABSTRACT

Congenital malformations of the maxillofacial region are significant, not completely decisive, medical and social problems. Recent literature data indicate a trend towards improvement. The aim of the study was to improve the effectiveness of treatment of children with bilateral cleft lip and palate due to pre surgical orthodontic treatment. For the period from 2011 to 2019, at the Department of Pediatric Dentistry and Orthodontics of the I.M. Sechenov First Moscow State Medical University of the Ministry of Health of the Russian Federation under supervision were 80 children with cleft lip and palate. From those children 56 were with bilateral cleft of the upper lip and palate from the neonatal period to 3 years, 28 patients made up the first group, which was treated according to the standard protocol with preliminary orthodontic preparation on removable devices, 28 patients made up the second group, which underwent partial opener osteotomy and fixed orthodontic apparatus with miniscrews and maxillary traction. Preoperative orthodontic preparation of 28 children with bilateral cleft and an indicator that 22 (78.6%) patients should not have fully achieved results between the interhuman and fragmentary alveolar process of the upper jaw. In the second group of patients, 27 (96.4%) patients showed a normal ratio of the intermaxillary bone and lateral fragments. The use of the developed orthodontic design with active elements and mini implants in 96.4% of cases requires the presence of prespiral orthodontic preparation, normalization of the position of the intercellular bone and shape, followed by primary cheilorinoplastics and in relation to additional uranoplastics, as well as the periodic stages of rehabilitation of patients with bilateral cleft lip and achieved thereby a stable aesthetic and functional result.

KEYWORDS: cleft lip, cleft palate, microimplants, cheiloplasty, orthodontic treatment.

INTRODUCTION

Congenital deformities are a topical medical and social problem which is still not fully resolved. Recent papers have shown a tendency for their growth, characterizing the health problems of the human population. As a rule, cleft lip and palate is a multifactorial condition, which can occur as an isolated malformation and be one of the symptoms

of congenital syndromes [Gilyova K et al., 2018].

Cleft lips and palate are one of the most common malformations of the maxillofacial region. It takes 3-4 places depending on congenital anomalies. Unlike other forms [Starikova N, Udolava N, 2012; Arsenina O et al., 2017], they are relatively rarer (15-25%).

According to data of WHO frequency of the children birth rate with the cleft of the lip and palate averaging in the world 1:600. Averaging on Russia is given rating according to data of different authors accounts for from 1 on 500 newborn to 1 on 750 newborn 4 [Gonchakov G, 2009; Mamedov A et al., 2019a].

ADDRESS FOR CORRESPONDENCE:

Olesya V. Dudnik, PhD
Sechenov University
8/2 Trubetskaya Street, Moscow 119991, Russia
Tel.: +79260900362
E-mail: oldudnik87@mail.ru

The anatomy of disorders of growth and development of the maxillofacial region in cleft lip and palate reflects not only the different length and magnitude of the defect that occurred in the process of embryonic development, but also the distant consequences of the disorder of growth and development in the absence of the integrity of the upper lip muscles and bone arch support, the presence of connection between the mouth and nose cavity. It is important to control individual biometric indices of the maxillary dentoalveolar arch for unification of orthodontic and surgical stages of correction in patients with cleft upper lip and palate in the course of diagnostics and treatment [Mamedov A et al., 2019b].

One of current problems of modern medicine is development and improvement of methods of early rehabilitation of children with congenital pathology of maxillofacial area as congenital anomaly of development leads to deformation of a midface, disharmony of development of a facial skeleton, roughly breaks functions of various vitals and systems, an esthetics of the person and has negative effect on formation of the psycho emotional status of the child. In most cases this pathology leads to an invalidization of children that emphasizes relevance of this medico-social problem in the world [Vodolatsky M, Vodolatsky V, 2009; Ershova O et al., 2017; Scacodub A et al., 2018].

It is believed that the use of early orthodontic treatments to prepare patients for primary surgery. To eliminate diastasis between the alveolar processes and correction of anomalies in the shape of the upper and lower arches with bilateral clefts and palate, modifying forming removable orthodontic appliances are used [Antonarakis G et al., 2016; Alzain I et al., 2017; Stock N et al., 2019].

The disadvantages of these devices are poor fixation in the conditions of a toothless jaw, the need for frequent visits to the doctor and the need for repeated replacement of devices. As a result, this leads to an increase in the duration of treatment and cannot always be achieved by alveolar processes of the upper jaw. The more diastases in the area of the alveolar processes, the more difficult it is to adapt the intermaxillary bone and lat-

eral fragments of the upper jaw [Costa B, 2016; Cruz C, 2016; Eriguchi M et al., 2018].

An analysis of the results of orthodontic removal of dentoalveolar deformities in patients with bilateral cleft shows that a special approach is needed in their resistance. Individual planning of orthodontic preparation, the choice of rational methods and means of orthodontic treatment depending on the age of the patient, changes in the planned forms of helio- and uranoplasty, the condition of the teeth, the type and type of cleft, the severity of dentoalveolar deformations [Pet M et al., 2015; Arshad A et al., 2017].

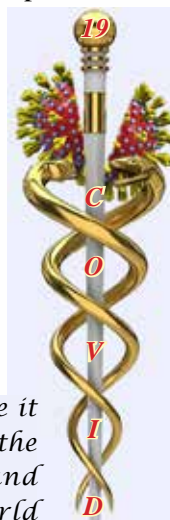The aim of the study was to improve the effectiveness of treatment of children with bilateral cleft lip and palate due to pre surgical orthodontic treatment.

MATERIAL AND METHODS

For the period from 2011 to 2019, at the Department of Pediatric Dentistry and Orthodontics of the I.M. Sechenov First Moscow State Medical University of the Ministry of Health of the Russian Federation under supervision were 80 children with cleft lip and palate. From those children 56 were with bilateral cleft of the upper lip and palate from the neonatal period to 3 years, 28 patients made up the first group, which was treated according to the standard protocol with preliminary orthodontic preparation on removable devices, 28 patients made up the second group, which underwent partial opener osteotomy and fixed orthodontic apparatus with miniscrews and maxillary traction.

Prior to surgery, a generally accepted clinical and laboratory examination was performed for all children with bilateral cleft of the upper lip and palate. In addition, patients were examined by a neonatologist, pediatrician and ENT doctor, since one of the leading places among concomitant pathology in children with cleft lip and palate was

*To overcome it
is possible, due to the
uniting the knowledge and
will of all doctors in the world*



occupied by the pathology of ENT organs. It should be noted that the pathology of ENT organs does not appear immediately, but at an age closer to one year.

Together with specialists, they interpreted the results of clinical and laboratory analyzes and functional studies. After the conclusion of the pediatrician about the general condition of the child and the possibility of surgical treatment, an anesthesiologist was consulted with a view to the possibility of general anesthesia.

From the pathology of the maxillofacial area, dental surgeons and orthodontists were interested in the following indicators: the condition of the oral mucosa; degree of protrusion of the intermaxillary bone; intermaxillary bone size; the degree of mobility of the jawbone; the angle of deviation of the jawbone from the midline of the face; the shape of the lateral fragments of the alveolar process of the upper jaw; the distance between the anterior points of the lateral fragments of the alveolar processes. After taking the diagnostic impressions, the marker contoured the borders of the lateral fragments of the alveolar bone and the middle intermaxillary bone with the vomer.

Then, models were photographed in a standard position and photos were transferred to a computer. Using the "AUTOCAD" program, the graphical shape of the crests of the lateral fragments of the alveolar processes, intermaxillary bone and vomer was obtained, where reference points were applied in the program, between which linear and angular measurements were performed.

In connection with the need to manufacture a fixed orthodontic apparatus for the choice of design (Fig. 1 a, b), we were interested in the following parameters: the severity of protrusion of the jawbone, the angle of deviation of the jawbone from the midline of the face, the distance between the anterior points of the alveolar processes of the lateral fragments of the upper jaw.

Micro implants (Absoanchor, Korea), designed specifically for use in orthodontics, were used as a support for the fixing elements of fixed orthodontic appliances with intraosseous fixation (Fig. 2).

Elastic chains, nickel-titanium springs (Fig. 3)




FIGURE 1. Modeling of the orthodontic apparatus (a), ready-made fixed orthodontic apparatus of a mechanical type of action (b).

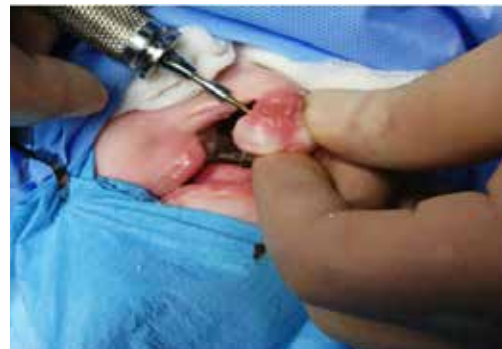

FIGURE 2. Placement of miniimplants in the intermaxillary bone.

were used as rods between the device and microscrews fixed on the maxillary bone.

The fixed apparatus was fixed using microimplants used in orthodontics under general anesthesia. After adapting to the apparatus, the screw was activated by 0.5 mm once every two days with simultaneous activation of elastic traction for one link in three days. Given the further growth of the intermaxillary alveolar process of the upper jaw in length after cheiloplasty, it is necessary not to completely close the fragments of the cleft of the upper jaw, but also to leave diastasis between them to the width of the temporary tooth. The duration of the active period ranged from 20 to 25 days.

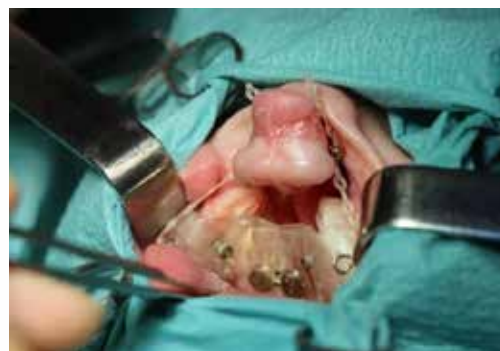

FIGURE 3. Fixation of the maxillary expanding apparatus, microimplants, rubber rods on the fragments of the upper jaw.

One of the important stages is the retention period, which ranged from 15 to 30 days. One month after reaching a favorable fragment ratio, simultaneous bilateral cheiloplasty was performed.

In all 56 children with bilateral cleft lip and palate, 56 control and diagnostic models were studied before and after the presurgical orthodontic preparation. Of these, 28 control and diagnostic models using conventional removable devices, 28 control and diagnostic models using fixed devices, fixed with microscrews.

In the study of diagnostic models of the jaw, attention was paid to the linear dimensions of the jawbone, the angle of deviation of the jawbone from the midline of the face, the angle of inclination of the lateral fragments of the alveolar process of the upper jaw. The results were subjected to statistical processing and entered into a specially designed table. In all the studies performed, the arithmetic mean (M), the standard deviation (delta), the mean square error (m) were calculated, and the correlation coefficient was determined. The significance of differences in the mean absolute and relative values was calculated using Student's criteria (t).

RESULTS

Preoperative orthodontic preparation of 28 children with bilateral cleft lip and palate in the first group showed that 22 patients (78.6%) could not fully achieve end contact between the intermaxillary bone and fragments of the alveolar process of the upper jaw. In addition, during the treatment process it was necessary to manufacture several removable devices and the average treatment period was 7 months. Due to the insufficient fixation of devices on fragments of the alveolar processes, damage to the oral mucosa was observed, requiring treatment and correction of the devices. The use of extraoral elastic traction did not allow to eliminate the medial displacement of the side fragments, required frequent replacement, and also caused irritation of the delicate skin of infants. With a low active ability, the children were restless, parents often refused further treatment with removable devices. In this

regard, the further implementation of the surgical stage of treatment was difficult, requiring repeated corrections and a long postoperative healing period.

In the second group of patients, it was possible to normalize the ratio of the maxillary bone and lateral fragments in 27 patients (96.4%). In 1 patient (3.6%), it was not possible to achieve the desired result due to individual non-engraftment of mini implants.

It should be noted that the use of the developed non-removable devices made it possible to eliminate the narrowing of the lateral fragments of the alveolar process of the upper jaw, due to the expansion screw built into the design. Which, in turn, was a favorable factor for the further formation of the jaws. After orthodontic preparation of the upper jaw on a fixed device, it was possible to surgically achieve the formation of the integrity of the alveolar arch, the elimination of protrusion of the intermaxillary bone, and the narrowing (expansion) of the lateral fragments of the alveolar process of the upper jaw.

To comparatively characterize the results of preoperative orthodontic preparation of children with bilateral cleft lip and palate using removable and fixed orthodontic structures, we conducted an anthropometric study of diagnostic models of the jaw. For comparative analysis of pre-surgical orthodontic preparation of children with bilateral lip and palate clefts with removable and non-removable orthodontic appliances we provided anthropometric study of diagnostic dental casts. Anthropometric data are in the forward table.

TABLE.
Pre-orthodontic preparation with removable maxillary appliance and fixed appliance for maxillary expansion and micro-implants

Age (months)	A removable apparatus		Fixed apparatus and microimplants	
	Premaxilla	Displacement Premaxilla	Premaxilla	Displacement Premaxilla
1	8.5±0.52	10.9±0.42	8.4±0.92	11.6±0.87
3	9.4±0.95	12.1±0.62	8.3±0.93	11.5±0.86
6	9.8±0.92	12.7±0.74	1.2±0.27	1.4±0.32
12	8.1±0.84	10.7±0.88	0.9±0.17	1.1±0.18

DISCUSSION

In patients of the first group, as a child grows with a bilateral cleft lip and palate, defects (diastasis) between the intermaxillary bone and lateral fragments of the upper jaw increase and reaches its maximum by 6 months. After cheiloplasty performed at this age, a statistically unreliable decrease in bone defect is noted. In patients of the second group, after preoperative preparation using fixed maxillary devices fixed with mini implants, full face contact between the maxillary bone and fragments of the upper jaw was achieved, which confirms the static processing of the results in the compared groups ($P<0.05$) (Fig. 4 a, b).

CONCLUSION

The use of the developed orthodontic design with active elements and mini-implants in 96.4% of cases allows to reduce pre-surgical orthodontic preparation, normalize the position of the maxillary bone and the shape of the upper jaw, followed by primary cheiloplasty and, in the future, uranoplasty, as well as reduce the rehabilitation time for patients with bilateral cleft lip and palate, thereby achieving a stable aesthetic and functional result.

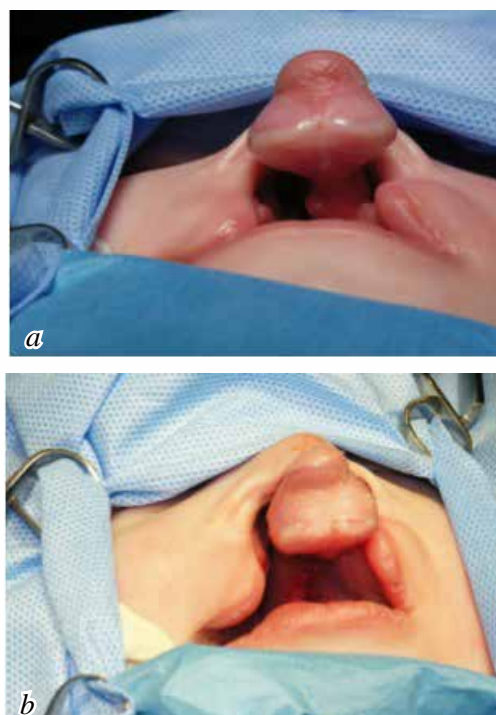


FIGURE 4. The location of the maxillary bone before orthodontic correction (a), after (b).

After the preoperative preparation using non-removable maxillary devices fixed with microimplants, a full-face contact between the maxillary bone and fragments of the upper jaw is achieved, which was confirmed by static processing of the material ($p<0.05$).

REFERENCES

1. Alzain I., Batwa W., Cash A., Murshid Z. Presurgical cleft lip and palate orthopedics: an overview. *Clin Cosmet Investig Dent.* 2017; 9: 53-59.
2. Antonarakis G.S., Tompson B.D., Paedo D., Fisher D.M. Preoperative Cleft Lip Measurements and Maxillary Growth in Patients With Unilateral Cleft Lip and Palate. *Cleft Palate-Craniofacial J.* 2016; 53(6): 198-207.
3. Arsenina O.I., Malashenkova E.I., Paschenko S.A. [Algorithm orthodontic treatment of patients with congenital cleft lip and alveolar bone before and after bone autoplasty] [Published in Russia]. *Stomatologiya (Moscow).* 2017; 5: 62-65.
4. Arshad A.I., Alam M.K., Khamis M.F. Assessment of complete unilateral cleft lip and palate patients: Determination of factors effecting dental arch relationships. *International Journal of Pediatrics Otorhinolaryngology.* 2017; 92: 70-74.
5. Costa B. Parent's experiences of diagnostics and care following the birth of a child with cleft lip and palate. *British Journal of Midwifery.* 2019;27(3): 151-160.
6. Cruz C. Presurgical Orthopedics Appliance The Latham Technique. *Oral Maxillofac Surg Clin N Am.* 2016; 28: 161-168.
7. Ershova O.Y., Dolgoplova G.V., Blochina S.I. Technological process of providing complex care to patients with alveolar process slits at the stages of preparation, operative treatment and post-reform rehabilitation. *Children's surgery.* 2017; 21(5): 258-261.
8. Eriguchi M., Watanabe A., Suga K., Nakano Y., Sakamoto T., Sueishi K., Uchiyama T. Growth of Palate in Unilateral Cleft Lip and Palate Patients Undergoing Two-stage Palatoplasty and Orthodontic Treatment. *Bull Tokyo Dent Coll.* 2018; 59(3): 183-191.

9. *Gonchakov G. V.* [The Basic principles of rehabilitation of children with congenital cleft of an upper lip and the palate in NPTs of medical care to children] [Published in Russian]//Materials III of the All-Russian scientific and practical conference Congenital and hereditary pathology of the head, face and neck of children: topical issues of complex treatment (Moscow). 2009. p. 104-105.
10. *Gilyova K.S., Chkadua T.Z., Romanova E.M., Butan S.B., Mohirev M.A., Yigitaliyev S.N., Askerov R.N., Chernenky M.M., Abdullayev K.F., Frolov S.S., Davidenco P.I, Arutyunov G.R.* Annals of plastic, reconstructive and aesthetic surgery. 2018; 1: 10-20.
11. *Mamedov Ad.A., Maclennan A.B., Admakin O.I., Morozova N.S., Mazurina L.A.* Multidisciplinary approach to cleft lip and palate treatment of children in a new born period: 59th Annual meeting of the Japanese teratological society; 13th World congress of the international cleft lip and palate foundation. 2019. p. 124.
12. *Mamedov A.A., Morozova N.S., Maklennan A.B., Volkov U.O., Mazurina L.A., Stebeleva U.V.* Surgical treatment protocol of early surgical reconstruction in patients with cleft lip and palate in newborn period: Scientific program Ist International Scientific Congress of Azerbaijan Society of Oral and Maxillofacial Surgeons. 2019. p. 57.
13. *Pet M.A., Marty-Grames L., Blount-Stahl M., Saltzman B.S., Molter D.W., Woo A.S.* The Furlow palatoplasty for velopharyngeal dysfunction: Velopharyngeal changes, speech improvements, and where they intersect. Cleft Palate-Craniofac J. 2015; 52(1): 12-22.
14. *Scacodub A.A., Mamedov AdA.,Kozlitina Yu.A.* [Cross-disciplinary interaction at diagnostics and treatment of a chronic recidivous stomatiti at children with various somatic pathology] [Published in Russian]//Materials of the international scientific and practical conference: from traditions to innovations. Under M.N. Kalinkin, B.N. Davydov, O.A. Gavrilova, I.A. Zhmakin, K.B. Bakanov's edition. 2018. p. 350-352.
15. *Starikova N.V., Udolava N.V.* The modern concept of correction of the position of alveolar process fragments in patients with lip slit, alveolar process and sky. Clinical stomatology. 2012; 4(64): 62-65.
16. *Stock N.M., Ridley M., Guest E.* Teachers' Perspectives on the impact of the Cleft lip and/or palate during the school years. The Cleft palate-craniofacial journal: official publication of the American Cleft Palate-Craniofacial Association. 2019; 56(2): 204-209.
17. *Vodolatsky M.P. Vodolatsky V.M.* [Clinic and features of treatment of children with an atypical cleft of face] [Published in Russian]// Mater. The III All-Russian scientific and practical conference Congenital and hereditary pathology of the head, face and neck of children: topical issues of complex treatment (Moscow). 2009: p 67-74.