



## REVIEW

**IN SEARCH OF MYOCARDIAL VIABILITY 20 YEARS LATER:  
METHODOLOGY, CLINICAL APPLICATIONS AND IMPLICATIONS****Montanaro C., Spoladore R., Salerno A., Maranta F., Torlasco C.,  
Gardini C., Margonato A., Fragasso G.\***

Department of Clinical Cardiology and Heart Failure Unit, Istituto Scientifico San Raffaele, Milano, Italy

**Abstract**

*Identification of reversible or non-reversible left ventricular dysfunction in patients with chronic myocardial dysfunction yields relevant clinical implications. The benefit of revascularizing a non-contractile, but alive viable myocardium is still object of discussion.*

*In this article, the issue of viability is approached from two perspectives: 1) review of methods that have been developed to identify potentially reversible myocardial dysfunction, and 2) evaluation of the risk-benefit ratio of coronary revascularization in dysfunctional myocardium.*

*In fact, albeit coronary revascularization of viable myocardium should be always considered mandatory, revascularization of apparently non-viable myocardium is still debated since it could improve the overall myocardial function and, therefore, improve prognosis.*

*In this article, the principal methods to detect the residual myocardial viability, their relative advantages or limitations and their clinical implication will be discussed.*

**Keywords:** myocardial infarction, viability, echocardiography, stress test, positron emission tomography, tomoscintigraphy.

Ischaemic heart disease (IHD) often leads to left ventricular (LV) dysfunction. The observation of a significant improvement in regional contractility in patients with IHD after different procedures, such as post-extrasystolic potentiation [Dyke S. et al., 1974], stress test [Rozanski A. et al., 1982] or administration of sympathomimetic amines [Horn H. et al., 1974], has led to the possibility to regain regional and global ventricular function. Following the evidence that ischaemic left ventricular dysfunction is potentially reversible, the identification of viable myocardium has become an issue of great interest.

Two pathological states are considered at the base of the potentially reversible ischaemic left ventricular dysfunction: myocardial stunning or myocardial hibernation. The condition of myocardial stunning is defined as a transient ischaemic episode resulting in contractile dysfunction that persists for a variable period of time, even if satisfactory restoration of coronary blood flow has been obtained [Braunwald E.,

Kloner R., 1982]. On the other hand, myocardial hibernation has been hypothesized to explain a persistent contractile dysfunction caused by a severe chronic reduction of coronary flow, partially or completely reversible with restoration of adequate perfusion [Rahimtoola S., 1985]. Therefore, the hibernating response of the heart can be considered a self-defence strategy of an "intelligent myocardium" that reduces contractile function in presence of a blood flow reduction (less blood, less work, but cells remain "alive") [Rahimtoola S., 1989].

Hypoperfused and hypocontractile myocardial segments may macroscopically appear normal, when examined at autopsy [Cabin H. et al., 1987], and may resume their contractile function after surgical revascularization [Bourassa M. et al., 1972].

The identification of hibernating myocardium, potentially responsive to revascularization, might be difficult: until recent times, viable but dysfunctional myocardium could be identified only retrospectively, by observing functional recovery after restoration of coronary flow. In fact, the markers of global and regional ventricular function have limited value in distinguishing between reversible and irreversible dysfunction [Chatterjee K. et al., 1972]. For this reason,

Address for Correspondence:

\* Clinical Cardiology - Heart Failure Clinic Istituto Scientifico San Raffaele  
Via Olgettina 60, 20132 Milano - Italy  
Tel.: 02 26437366, Fax: 02 26437358  
E-mail: gabriele.fragasso@hsr.it

in the course of the last 20 years, several imaging techniques have been developed to assess residual tissue viability after myocardial infarction (MI) and to optimize patients' selection for revascularization.

The aim of present review is to describe the main available tools for detection of myocardial viability and their technical limitations, as well as to discuss their clinical relevance and consequent practical attitudes in the light of recent studies.

### **Identification of Residual Myocardial Viability**

#### *Role of conventional scintigraphic techniques.*

Among the agents available for study of the regional myocardial perfusion, Thallium-201 (Tl-201) is undoubtedly the most used for the assessment of residual viability.

*Tl-201 tomoscintigraphy:* It is based on the principle that myocardial perfusion and integrity of the cellular membrane must be necessarily conserved, so that Tl-201 can accumulate in the myocardial cell. Tl-201 is a potassium analogue actively transported by Na<sup>+</sup>/K<sup>+</sup>-ATPase pump through the cellular membrane of the myocardiocyte [Weich H. et al., 1977]: its initial uptake is mainly determined by perfusion, with a high first pass myocardial extraction fraction (about 80%), whereas the subsequent retention depends on the cellular membrane integrity.

Different protocols have been proposed for Tl-201 and the most used is certainly the one with a reinjection of the tracer following the acquisition of late sequences after stress test. Imaging is performed immediately after stress and 3-4 hours later and can demonstrate reversible perfusion defects, indicating ischemic areas, or stable defects consisting of severely underperfused segments without significant residual redistribution. In order to distinguish scarred from hibernating myocardium, a second Tl-201 dose is injected immediately after the last acquisition of images at 3-4 hours after stress and new images are obtained. Residual viability is then proved in reinjection images when the defect demonstrates a significant "filling" (generally defined as an increase in tracer uptake of more than 10%) or in case of lack of filling, but with tracer activity greater than 50% in stable defect. A "differential uptake" is a phenomenon, in which reversible defects at redistribution images seem to get a worse defect after reinjection [Dilsizian V., Bonow R., 1992]. Apparently, this is due to a smaller increment in regional Tl-201 uptake after reinjection in ischaemic areas compared to normal myocardium. Similarly, a reverse-redistribution

pattern has also been associated with the presence of tissue at risk [Fragasso G. et al., 1994].

The advantage of this stress-redistribution-reinjection protocol is that it allows an effective evaluation of patients with ischaemic cardiomyopathy and gives information on both viability and inducible ischaemia after stress. In order to accelerate the procedure timing, reinjection may be carried out immediately after stress imaging and 1 hour later [Van Eck-Smit B. et al., 1993]. However, the accuracy of Tl-201 protocols are sub-optimal, especially regarding specificity [Arnese M. et al., 1995; Bax J. et al., 1997].

Other perfusion tracers, beside Tl-201, may be used for studying viability.

*Technetium-99m sesta methoxyisobutylisonitrile (MIBI) (Tc-99m):* Tc-99m labelled isonitriles (such as sestaMIBI) like Tl-201 need functional integrity of the cellular membrane for their retention; they accumulate inside mitochondria for progressive electrical gradient between extracellular space, cytosol and mitochondria [Beanlands R. et al., 1999]. A low myocardial extraction rate and the absence of a significant redistribution represent intrinsic disadvantages compared to Thallium, as observed in patients with chronic ischaemic cardiomyopathy and LV dysfunction [Sciagra R. et al., 1997].

A better diagnostic accuracy of Tc-99m sesta-MIBI through quantitative analysis of the tracer activity inside the uptake defects may be obtained via administration of nitrates before rest injection, with the purpose of improving basal flow and, as a consequence, tracer uptake [Bisi G. et al., 1994].

*Fatty acid imaging:* Myocardial viability may also be detected by injecting radio-iodinated fatty acids [Chappuis F. et al., 1990; Murray G. et al., 1992; Tamaki N. et al., 1992]. The rational basis of the use of this tracer is the metabolic shift of ischaemic myocardium from long-chain fatty acids (aerobic metabolism) to glucose. In particular, 123 I-(p-iodophenyl)-3-(R,S)-methylpentadecanoic acid (BMIPP) is a fatty acid tracer that seems to detect "ischaemic memory". A defect of BMIPP uptake is indicative of recent ischaemia, even if perfusion has returned to normal levels. The clinical use of these tracers is limited by the difficulty in extrapolating the specific metabolic pathway [Visser F. et al., 1985] and by the rapid dynamics of their metabolism.

*Positron emission tomography (PET):* In order to obtain the best accuracy in detecting viability, an integrated investigation of function, perfusion and

metabolism is needed [Bax J. et al., 2000]: PET is considered the gold standard in evaluating the metabolic activity of akinetic myocardial segments.

According to the standard protocol for the study of myocardial viability, myocardial flow is evaluated by rubidium-82, nitrogen-13-labelled ammonia or oxygen-15-labelled water, while metabolism is evaluated by fluorine-18-labelled fluorodeoxyglucose (FDG). This glucose analogue is carried inside the cell and then phosphorylated [Ratib O. et al., 1982]; its uptake is increased in hypoperfused areas [Brunken R. et al., 1986; Fudo T. et al., 1988], which, after revascularization, regain their contractility [Tillisch J. et al., 1986].

Normal myocardium obtains its energy mainly from oxidation of fatty acids (95%) and glucose accounts only for a minor part; when myocardial oxygen availability is reduced for the presence of flow-limiting coronary lesions, myocardial metabolism shifts to a higher consumption of glucose through both the residual aerobic pathway and the anaerobic glycolysis.

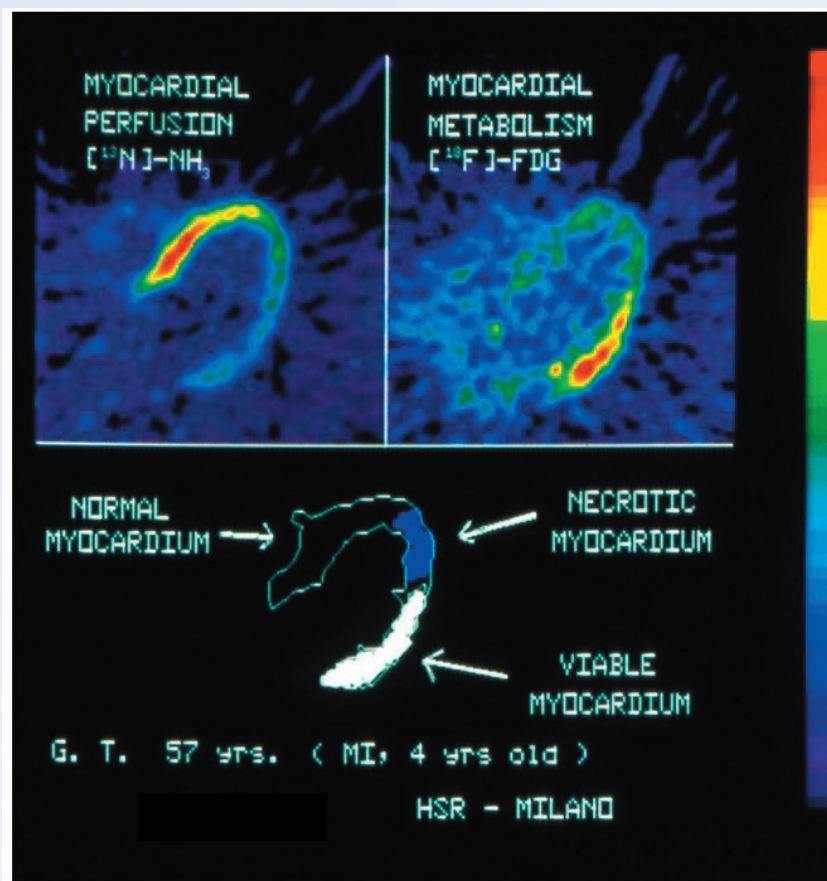
In necrotic myocardium, the FDG uptake is absent. In contrast, in viable but hypoperfused areas (hibernating) or in stunned myocardium, FDG uptake is normal or increased, whereas perfusion is re-

duced in the first case (FDG/flow mismatch) and normal or slightly reduced in the second one [Desideri A. et al., 2005] (Figure).

In a previous study, we confirmed the presence of increased glucose uptake in the majority of recent myocardial infarctions and demonstrated that the extension of residual tissue viability is inversely related to the time elapsed from acute event [Fragasso G. et al., 1993]. A more recent study has confirmed the temporal dependence of residual viability [Bax J. et al., 2003].

FDG uptake has been shown to allow the identification of those territories that will improve their function after revascularization; the mismatch pattern has been demonstrated to be an accurate marker for distinguishing viable from fibrotic myocardium, with a negative and positive predictive value of about 85% [Bax J. et al., 2001]. Segments with significant reductions in both blood flow and FDG uptake have only a 20% chance of functional improvement with revascularization, whereas hibernating territories as defined by PET have approximately 80% chance of functional improvement following revascularization [Tamaki N. et al., 1995].

Outcome after coronary artery bypass grafting (CABG) may be accurately predicted by PET de-



**Figure.** Myocardial perfusion (upper left) and metabolism (upper right) as assessed with N13-Ammonia and F18-Fluorodeoxyglucose, by positron emission tomography, in a patient with a 4 year old myocardial infarction. The lower part of the picture represents a schematic summary of the combined cardiac scan. The septum appears perfused and without glucose uptake, indicating normal myocardium. The apex is neither perfused nor metabolically active and indicates necrotic myocardium. The free wall is not perfused, but shows significant uptake of the glucose analogue, indicating therefore the presence of residual viability.

rived viability information and clinical and angiographic data. K.S. Lee and co-workers evaluated the prognostic importance of the presence of a viable myocardium and its interaction with myocardial revascularization in patients with LV dysfunction and resting perfusion defects after myocardial infarction. They found that FDG (+) myocardium and absence of revascularization independently predicted ischaemic events: 48% of medically-treated FDG (+) patients experienced nonfatal ischaemic events compared with only 8% of FDG (+) revascularized patients [Lee K. et al., 1994]. Similarly, a study by D.V. Eitzman described a cardiac event rate of 50% in patients with depressed LV function and presence of myocardial hibernation [Eitzman D. et al., 1992]. FDG uptake in revascularized patients was defined as the best predictor of events also in a series of postinfarction patients followed up by N. Tamaki and associates [Tamaki N. et al., 1993].

A direct correlation between the number of “mismatch” segments with PET and the improvement of ejection fraction after revascularization has also been observed [Pagano D. et al., 1998].

While in the setting of very severe, LV dysfunction PET may have an advantage over Single Photon Emission Computed Tomography (SPECT) [Marin-Neto J. et al., 1998]; in moderate LV dysfunction PET or SPECT imaging have the same ability to detect myocardial viability and no difference was found in patient outcome, when management decisions were based upon the results of either technique [Siebelink H. et al., 2001].

Among other different approaches for characterising viable myocardium through PET, we would like to mention:

- 1). evaluation of oxidative metabolism with carbon-11-labelled acetate that in one study has been demonstrated to be superior to FDG in predicting functional improvement after revascularization [Gropler R. et al., 1993];
- 2). evaluation of dysfunctional myocardium perfused by oxygen-15-labelled water [Yamamoto Y. et al., 1992];
- 3). analysis of tissue rubidium-82 uptake kinetics in dyssynergic segments [Gould K. et al., 1991].

However all these data were preliminary and were not followed by validation studies in more numerous populations. Therefore, their real clinical value remains unclear.

### **Role of echocardiography.**

**Rest echocardiography:** Myocardial viability may be initially evaluated by bidimensional rest echocardiography. Severe thinning, as for example a reduction to less than 6 mm of the end-diastolic wall thickness, is an indirect marker of absent viability. Many studies showed that severely thinned cardiac segments cannot recover their contractile function after revascularization [Faletra F. et al., 1995; Cwajg J. et al., 2000; La Canna G. et al., 2000]. Moreover, the presence of an advanced LV remodeling caused by high ventricular volumes and by the spherical shape of left ventricle is associated to a low probability of recovery of contractile function after revascularization [Vanoverschelde J. et al., 1995; Yamaguchi A. et al., 1995; Rizzello V. et al., 2004]. Therefore, careful analysis of rest echocardiography may be helpful to predict functional recovery; however additional echocardiographic characteristics may be necessary to evaluate the presence of myocardial viability.

**Stress echocardiography:** Stress echocardiography may be performed with either physical exercise or pharmacological stimulation and pacing. Since the evaluation of viability may turn out to be difficult through stress echocardiography with physical exercise, application of pharmacological stimulation has become very popular. Dobutamine, dipyridamole or isoproterenol are generally used.

*Isoproterenol* is a synthetic catecholamine that stimulates both beta1 and beta2 adrenergic receptors (not alpha receptor); it affects the heart in an inotropic and chronotropic positive way. In addition, isoproterenol causes arterial and bronchial dilation.

In current clinical practice, dipyridamole and dobutamine are the only used stimuli. Even if both agents may be used to evaluate viability and ischaemia, dobutamine stress remain the most used echocardiographic test.

*Dobutamine* stress echocardiography has emerged as an important non-invasive clinical tool for the detection of the contractile reserve of hibernating myocardium. It has been demonstrated that contractile reserve recruitment after low-dose dobutamine infusion (5-15  $\mu\text{g}/\text{kg}/\text{min}$ ) accurately predicts functional recovery after revascularization [Bax J. et al., 1996; Vanoverschelde J. et al., 1996]. After low-dose dobutamine infusion, viable myocardium may show an improvement of parietal kinetics or an ischaemic response [Afridi I. et al., 1995].

A contractile response to dobutamine appears to require the presence of at least 50% of viable myocytes in a given segment and correlate inversely with the extent of interstitial fibrosis on myocardial biopsy. In particular, the biphasic response (recruitment of myocardiocytes and contractility improvement after low-dose followed by a worsening after high-dose because of subendocardial ischaemia) is better correlated with both regional and global functional regaining after revascularization [Nagueh S. et al., 1997; Cornel J. et al., 1998; Hernandez-Pamploni M. et al., 2003; Rizzello V. et al., 2003]. Therefore, testing at various doses is required for optimal assessment of myocardial hibernation. If biphasic response is predictive for functional recovery, the amount of dysfunctional but viable myocardium may better predict long term outcome [Sawada S. et al., 2003]. There is a linear correlation between the number of viable segments and the improvement of global systolic function after revascularization [Bax J. et al., 1999].

Evaluation of myocardial viability through stress echocardiography may be difficult in patients with poor acoustic window or at higher risk of ventricular arrhythmias. The use of tissue harmonic and contrast imaging allow a better visualisation of the endocardial border and a better evaluation of contractile function [Porter T. et al., 1994; Falcone R. et al., 1995; Kasprzak J. et al., 1999; Franke A. et al., 2000; Sozzi F. et al., 2000]. Even among expert technicians, a significant interobserver variability has been observed and this may affect sensitivity in comparison to quantitative nuclear imaging. Radio-nuclide myocardial perfusion imaging as thallium imaging, identifies segments with fewer viable myocytes. The two techniques yield equivalent sensitivity among segments with more than 75% viable myocytes (78 vs 87%), but dobutamine presents a much lower sensitivity among segments with 25 to 50% viable myocytes (15 vs. 82%) [Baumgartner H. et al., 1998]. Atropine may be given with dobutamine to enhance the diagnostic value of the technique.

As regard to the ability to predict recovery of contractility of hibernating myocardium after revascularization, it was found that this is better correlated to increased contractility on low-dose dobutamine stress exercise (LD-DSE) than to SPECT and PET imaging. In a meta-analysis pooling 925 patients from 28 studies, J.J. Bax and colleagues [Bax J. et al., 2001] determined sensitivity, specificity,

and positive and negative predictive values of LD-DSE to predict functional recovery following revascularization as 81%, 80%, 77% and 85%, respectively. The highest positive predictive value was seen with dobutamine echocardiography, with intermediate values for FDG-PET, rest-redistribution Tl-201 SPECT and technetium- sestaMIBI SPECT and the lowest value for reinjection Tl-201 SPECT [Bax J. et al., 2001; Underwood S. et al., 2004]. Dobutamine stress echocardiography can be used to predict the likelihood of recovery after CABG with accuracy similar to PET scanning [Baer F. et al., 1996]. However, it is less accurate, when there is a totally occluded coronary artery. The negative predictive value is higher than the positive predictive value in each considered technique, but highest negative predictive values are observed with FDG-PET, reinjection Tl-201 SPECT and dobutamine echocardiography, while lower values were noted for rest-redistribution Tl-201 SPECT and Tc-99m-sestaMIBI SPECT.

*Tissue Doppler echocardiography (TDE) / strain rate imaging (SRI):* SRI involves mathematical subtraction of the whole heart or translational motion from regional thickening velocity using a transmural data set from color-coded TDE. This can overcome subjective interpretation of wall motion scoring with traditional dobutamine echocardiography. In fact, when this technique is used together with low dose dobutamine (combination of SRI and wall motion scoring), it significantly increases the sensitivity to predict recovery of function after CABG compared to wall motion scoring alone (82 vs 73%) [Hane-kom L. et al., 2005].

*Pulsed-wave Tissue Doppler Imaging (TDI):* This technique provides a further progress in myocardial viability evaluation. During stress echocardiography TDI measures the wideness, the velocity and the time-intervals relative to myocardial function, providing an objective quantification of contractile performance. It allows measurement of longitudinal velocity of the left ventricle with a high temporal resolution [Zamorano J. et al., 1997]. Colour TDI allows evaluation of a myocardial velocity gradient from epicardium to endocardium. It has been demonstrated that these parameters are extremely sensitive in detecting myocardial viability during dobutamine stress echocardiography [Gorcsan J. 3rd et al., 1998; Tsutsui H. et al., 1998].

*Enoximone stress echocardiography:* Enoximone has been suggested as an alternative stressor to do-

utamine. It is a non-glycosidic non-catecholaminergic inotropic agent that operates via selective inhibition of phosphodiesterase III, the enzyme responsible for the continuous intracellular cyclic-AMP degradation. An increase in intracellular cyclic-AMP consecutively increments calcium intake into cells, resulting in an improvement of cardiac inotropism [Lu C. et al., 2000]. As a consequence, enoximone may be regularly used in association to echocardiography, as a substitute for dobutamine. The possible role of enoximone stress echocardiography was evaluated in chronic Coronary Artery Disease (CAD) with LV dysfunction and compared to dobutamine [Lu C. et al., 2000]. Both increased heart rate, but enoximone did not cause systolic blood pressure changes. Concordant results were seen with these techniques, but enoximone yielded higher sensitivity (88 vs 79% for dobutamine) and negative predictive value (90 vs 84%) in predicting functional recovery after revascularization; specificity and positive predictive values were similar. Recently, a comparison of enoximone echocardiography with positron emission tomography for the detection of residual viability has shown a fair concordance between the two techniques [Lu F. et al., 2010].

*Rest electrocardiogram (ECG):* Nuclear imaging suffers from important limitations such as being complex, expensive and poorly available in most clinical centres. Stress echocardiography is limited by the fact that patients suffering from ischaemic heart disease do not often present an acceptable acoustic window and, when test is feasible, it relies on subjective interpretation and on operator's experience. On the contrary, electrocardiographic stress test, to which patients are submitted in the post-infarction period for diagnostic and prognostic reasons, is universally available and relatively cheap. Clearly, electrocardiography cannot provide information about metabolic activity of myocardial cells, but can only assess the presence of residual ischaemia, induced by exercise, in the infarcted area. Therefore, the adoption of stress test in order to evaluate the presence of residual viability is linked to the notion that only viable myocardium could develop ischaemia and, consequently, typical ECG abnormalities.

However, in presence of previous myocardial infarction, the significance of ST-segment elevation and T-wave pseudonormalization is controversial. In fact, whereas some studies consider these alterations due to transient ischaemia [Dunn F. et al., 1980; Fox K.

et al., 1982], others have suggested that purely mechanical factors (e.g.: aneurysm and consequent bulging of the left ventricle) may cause ST-segment alterations, even in absence of ischaemia [Stiles G. et al., 1980]. In making an attempt to identify simple, non-invasive and less expensive diagnostic methods for identifying viable and potentially recoverable myocardial tissue, the significance of transient ST-segment elevation and T-wave pseudonormalisation occurring during exercise in the leads interested by myocardial necrosis [Margonato A. et al., 1992] has been investigated.

A stable perfusion defect, indicative of myocardial necrosis, was observed in all study patients with previous myocardial infarction. Additionally, a partially reversible perfusion defect was observed in 94% of patients with ST-segment elevation and in 50% of patients with T-wave alterations. Patients with reversible ischaemia in infarcted areas had a residual critical stenosis at the level of the responsible coronary or a complete occlusion. No patient had angiographic evidence of left ventricular aneurysms. Thus, ST-segment elevation during stress test in the post-infarction period can be considered as a clinical indicator of residual myocardial viability and potentially useful for assessing indication to revascularization [Margonato A. et al., 1992].

In order to further investigate this finding, in a subsequent study fourteen patients were submitted in the early post-infarction period to percutaneous angioplasty of a residual stenosis of the culprit vessel. During balloon inflation, reversible ST-segment elevation developed in the same leads, which showed ST-elevation involved during stress test. In twelve of these patients, perfusion tomography showed a partially reversible perfusion defect in the infarcted area indicative of viable myocardial tissue and prone to develop ischaemia. The significance of exercise-induced ST segment elevation was also validated by positron emission tomography of fluorodeoxyglucose distribution; again, this simple ECG evaluation showed a great diagnostic accuracy similar to that obtained by PET [Margonato A. et al., 1995]. In a subsequent study, the presence of arrhythmias during exercise in patients with previous myocardial infarction was also related to the presence of viable myocardium [Margonato A. et al., 1996].

Altogether, these studies indicate that an accurate analysis of a simple stress ECG can provide important (but simple) information concerning the pres-

**Table.**

Sensitivity, specificity, PPV, and NPV for the different techniques from the available studies  
(modified from *Bax J.J. et al., 2001*)

Technique	Sensitivity Mean (95% CI)	Specificity Mean (95% CI)	PPV Mean (95% CI)	NPV Mean (95% CI)
Dobutamine echo (LDDE + HDDE)	81 (80-82)	80 (78-81)	77 (76-78)	85 (84-86)
201 Ti rest-redistribution	86 (84-88)	59 (56-92)	69 (67-71)	80 (77-83)
201 Ti reinjection	88 (86-90)	50 (47-53)	57 (54-60)	83 (80-86)
99mTc-based tracers	81 (78-84)	66 (63-39)	71 (68-74)	77 (74-80)
FDG PET	93 (91-95)	58 (54-62)	71 (68-74)	86 (83-89)
Direct comparison of DE and nuclear DE	74 (71-77)	78 (75-81)	84 (81-87)	69 (65-73)
Nuclear	90 (88-92)	57 (53-60)	75 (72-78)	80 (76-84)

**Notes:** LDDE - low-dose dobutamine echocardiography; HDDE - high-dose dobutamine echocardiography; PPV - positive predictive value; NPV - negative predictive value. DE- delayed-enhancement

ence of viable myocardium, without necessarily recurring to elaborate, expensive and scarcely available investigations [*Fragasso G. et al., 1993b*].

**Additional radiological techniques**

**Contrast-enhanced Magnetic Resonance Imaging (MRI):** MRI is a relatively new technique for the detection of viability. Several studies have demonstrated the value of cardiac MRI in assessing wall thickness, contractile reserve, perfusion and transmural extent of necrosis for predicting LV functional recovery. LV end-diastolic wall thickness of less than 5.5 mm has been used as a marker of scar tissue [*Kaandorp T. et al., 2005*]. The evaluation of contractile reserve by MRI is similar to echocardiography, but the available MRI studies have used only low-dose dobutamine infusion. Contrast hyper-enhancement on delayed rest MRI is defined as region with increased intensity on T1-weighted images acquired more than 5 min after the intravenous administration of the paramagnetic contrast agent. The mechanism underlying contrast hyper-enhancement is related to the interstitial space between collagen fibres, which is larger in scar tissue than in normal myocardium, determining therefore the accumulation of the contrast agent in infarcted regions.

In animal models, excellent agreement between the extent of hyper-enhancement on contrast-enhanced MRI and histologically determined infarct size has been demonstrated [*Kim R. et al., 1999*]. The major advantage of contrast-enhanced MRI is related to its superior spatial resolution, which allows differentiation between transmural and subendocardial necrosis.

Studies with contrast-enhanced MRI showed that the likelihood of recovery of function after revascularization correlated with the transmural extension of the infarction. The degree of hyperenhancement is a very good indicator of potential improvement in function; improvement in function decreases progressively as the transmural nature of scar tissue increases [*Schinkel A. et al., 2007*].

Moreover, MRI may be particularly useful for evaluating impaired resting myocardial blood flow in hibernating regions beyond a coronary stenosis, myocardial scarring as a result of revascularization procedures and improvement in regional myocardial contractility after surgical ventricular reconstruction [*Selvanayagam J. et al., 2004; 2005*].

There is a great amount of data showing that delayed-enhancement MRI (DE-MRI) is comparable or better than alternative techniques in identifying viable myocardium. A. Wagner and colleagues [*Wagner A. et al., 2003*] observed that DE-MRI and SPECT were able to detect transmural infarcts at similar rates but, in case of subendocardial infarcts, 47% of segments (13% of patients) detected by DE-MRI were missed by SPECT. Another study comparing DE-MRI to SPECT in the setting of acute myocardial infarct showed that DE-MRI was more sensitive than SPECT in detecting all infarcts (97% vs 84%) [*Ibrahim R. et al., 2007*]. The predictive value of MRI has been shown to be relatively limited in segments with 1 to 49% hyperenhancement, but low-dose dobutamine MRI may be particularly valuable with a sensitivity and specificity approaching 90% [*Wellnhofer E. et al., 2004*]. Several studies have confirmed that late

gadolinium enhancement occurs in dysfunctional myocardium that is viable and displays improved contractile function in response to low dose (5 to 10  $\mu\text{g}/\text{kg}/\text{min}$ ) dobutamine infusion: regions with enhancement, where the infarct is transmural display no contractile activity in response to dobutamine, while territories that have non-transmural necrosis display a fair response to dobutamine [Bernhard L. et al., 2001].

Since the size of hyperenhancement may decrease with time, there may be predictive value in assessing non-hyperenhanced regions of the ventricle. One study demonstrated the value of measuring the non-enhancing wall thickness to predict improvement in systolic wall thickening [Ichikawa Y. et al., 2005].

Various studies are now available comparing DE-MRI to PET, often considered the gold standard for determining myocardial viability, as discussed before. All these studies produced concordant findings, showing a good correlation between the two techniques. C. Klein and colleagues [Klein C., et al. 2002] studied 31 patients with severe ischemic LV dysfunction, demonstrating for the first time that DE-MRI as a marker of myocardial scar correlated well with PET data ( $p < 0001$ ): DE-MRI areas of hyperenhancement showed close correspondence with areas of decreased flow and metabolism seen on PET. Moreover, DE-MRI, due to greater spatial resolution, was also able to differentiate myocardial scar in the form of subendocardial scar, significantly more accurately than PET. H. P. Kühl also obtained similar results examining 26 patients with chronic coronary artery disease and severe LV dysfunction [Kühl H. P., et al. 2003]. Considering as optimal cut-off a value of 37% segmental hyperenhancement, the ability of DE-MRI to detect nonviable myocardium, as defined by PET, yielded a sensitivity and specificity of 96% and 84%, respectively (Table).

**MRI myocardial tagging:** This is a non-invasive method that quantifies local myocardial segment shortening throughout the LV myocardium at sites across the LV wall thickness. Quantitative analysis of regional intramural function can be performed independent of accurate border detection, when this technique is used in conjunction with two-dimensional strain analysis [Götte M. et al., 2001].

“Strain”, as described in echo section, refers to fractional or percentage change from baseline, unstressed dimension. It reflects deformation of a structure, and when applied to the myocardium, strain directly describes the contraction/relaxation

pattern. Strain rate is the rate of this deformation [Abraham T., Nishimura R., 2001]. When combined with low dose dobutamine, MRI myocardial tagging can quantify the amount of myocardial viability after an acute MI and may provide prognostic information. In patients with a first reperfused MI, a normal increase in shortening within the midwall and sub-epicardium, but not the subendocardium, during a low-dose dobutamine infusion predicted functional recovery eight weeks after the MI [Geskin G. et al., 1998]. A second report compared dobutamine MRI tagging with thallium and tetrofosmin SPECT: the sensitivity and specificity of dobutamine MRI was 50 and 81%, respectively; SPECT imaging with thallium or tetrofosmin had higher sensitivity (76 and 66%, respectively), but lower specificity (44 and 49%, respectively) [Gunning M. et al., 1998].

**Computed Tomography (CT):** Assessment of myocardial viability by CT is based on the relative tissue contrast concentrations on postcontrast imaging. Various studies indicate that contrast-enhanced CT can accurately define acute and chronic infarcts showed as regions of hyperenhancement approximately 5 minutes after contrast injection. Areas of microvascular obstruction were characterized, on the contrary, by hypoenhancement [Hoffmann U. et al., 2004; Lardo A. et al., 2006]. J.F Paul and colleagues [Paul J., et al. 2005] studied 34 patients comparing late enhancement on contrast-enhanced CT to SPECT in defining residual perfusion defects and infarct size, and defined CT sensitivity and specificity of 93% and 100%, respectively. However, further studies are necessary to evaluate the exact role of CT for the evaluation of tissue viability.

### **Invasive Techniques**

**Electroanatomic mapping:** Electromechanical endocardial mapping, performed with a nonfluoroscopic catheter-based system (NOGA TM, Biosense) was first described in 1996 [Ben-Haim S. et al., 1996]. This technique offers a real-time, three-dimensional reconstruction of the endocardial surface providing simultaneous electric (amplitude of endocardial electrical signals), anatomic, and mechanical mapping (regional wall motion contractility by measuring the variability in distance between each individual point and its surrounding points on the map during the cardiac cycle) of the endocardium. Reproducibility and accuracy [Gepstein L. et al., 1997 a; b; Smeets J., et al., 1998] of the system have

been assessed and compared with echocardiography. Both local shortening and unipolar voltage have been shown to agree well with echocardiographic wall-motion abnormalities [Lessick J., 2000].

NOGA endocardial mapping was originally introduced for mapping arrhythmias and recently it has been recognized to have a role in distinguishing between infarcted and ischemic, but still viable, myocardium. Hibernating myocardial segments have been shown to exhibit significantly higher unipolar voltages (local electrical activity was recorded at a distinct point on the map). Further analysis has shown that a mean unipolar voltage of 9.0 mV at NOGA in the region of interest for prediction of functional recovery [Gyöngyösi M. et al., 2000] yields a predictive accuracy of 71%, and sensitivity and specificity of 72%.

In one report on viability search directly compared to the results of revascularization, the diagnostic performance of electroanatomic mapping was not as good as that of radionuclide myocardial perfusion imaging with PET or SPECT [Wiggers H. et al., 2003].

However, NOGA remains a very attractive technique for the evaluation of myocardial viability. A large study comparing NOGA-driven versus PET- or SPECT-driven revascularization of dysfunctional myocardial areas would answer to the question whether NOGA viability assessment could be of clinical value.

#### **Present clinical relevance of the identification of viable myocardium**

The pioneer of the viability issue was Shahbudin Rahimtoola, who first drew attention to the particular condition of myocardial areas, which are non-contracting, yet retained viable. At the time, it was defined as myocardial “hibernation” [Rahimtoola S., 1982]. In this context, a special chapter is occupied by the functional significance of chronic coronary total occlusions (CTO).

In fact, the “patent artery hypothesis” postulates that a patent coronary artery, even if tributary to a completely necrotic area could, in the long term, improve prognosis in patients with previous infarction. Several studies confirmed the advantage of reopening CTO [Suero J. A. et al., 2001]; in fact, even late coronary recanalization in patients with myocardial infarction (in the short- [Sheiban I. et al., 2001] and medium [Pizzeti G. et al., 1996] term), has been shown

to prevent long-term ventricular remodelling, regardless of the presence of viable tissue.

Indeed, hibernation has been referred to as a state of incomplete adaptation to ischaemia, where myocytes progressively deteriorate and finally succumb to cell death and replacement fibrosis [Elsässer A. et al., 1997]. Clinical correlates of such progressive deterioration do exist. The prevalence of flow-metabolism mismatches after an acute myocardial infarction declines with time [Fragasso G. et al., 1993b; 1997], and a delay in surgical revascularization of viable myocardium can be associated with loss of potential improvement in global left ventricular function [Beanlands R. et al., 1998]. In fact, the myocardium that has survived the initial ischaemic insult, but remains severely underperfused for prolonged periods of time, may eventually succumb to necrosis and be replaced by scar tissue. On the other hand, the Coronary Artery Surgery Study [Alderman E. et al., 1983] has shown that surgical revascularization of patients with low left ventricular ejection fractions (<26 %) significantly improves 7-year survival, when compared to non-surgical treatment, regardless of the presence of residual viability. Indeed, effective blood flow within infarcted areas may limit remodeling by enabling the formation of a firmer myocardial scar. Avoidance of unfavorable left ventricular geometry results in many secondary later benefits, such as reduction of wall stress, prevention of volume overload, hypertrophy and improvement of ejection fraction [Pizzeti G. et al., 1996; Horie H. et al., 1998]. The magnitude of the necrotic area plays a significant role in determining this process [Klein M. et al., 1967], but the size of the infarct is not the only factor influencing ventricular expansion, which is in fact more often associated with total occlusion of the infarct-related vessel [Lamas G., Pfeffer M., 1986; Hochman J., Choo H., 1987; Pfeffer M., Braunwald E., 1990; Leung W., Lau C., 1992]. Left ventricular dysfunction remains the strongest predictor of cardiac death after myocardial infarction, regardless of fluorodeoxyglucose uptake within the infarct area [Lee K. et al., 1994].

Finally, in addition to the infarcted tissue, areas that are distant from infarction can also serve as a feature of altered metabolism and, most likely, of cellular suffering. Revascularization of the infarcted area could be helpful in reducing supplementary workload in remote areas, thus contributing to cardiac remodelling prevention.

Therefore, on the basis of the existing literature, the potential progression of reversibility to irreversibility of contractile dysfunction dictates prompt therapeutic interventions that reverse this course. However, in patients with ischaemic cardiomyopathy, the lack of detection of residual tissue viability does not at present necessarily prevent cardiologists from trying to ameliorate blood supply. Maximization of blood supply to non-viable areas may not reverse the course from reversibility to irreversibility of myocardial dysfunction, but it can at least halt it. Though revascularization procedure-related morbidity and mortality rates increase as left ventricular systolic function worsens, yet substantial benefit can be noted in patients with profoundly reduced ejection fraction. Since the prognosis with medical therapy is so poor in these patients, they have the most to gain from early revascularization, when feasible.

#### **The open artery hypothesis**

Although total CTO is a relatively frequent angiographic feature, around 10% of coronary percutaneous interventions represent attempts to re-open a totally occluded coronary artery [Anderson H. et al., 2002].

However, the decision of re-opening an occluded coronary artery should be based on the real possibility of restoring anterograde coronary flow and reducing angina and/or improving left ventricular function. As a natural consequence, this approach should imply the documentation of viable myocardium within the tributary tissue.

Several studies have tried to evaluate the objective clinical role of reopening CTOs. The TOAST-GISE [Olivari Z. et al., 2003] trial, has investigated the success rate of acute and 12-month clinical outcome of percutaneous coronary intervention (PCI) for CTO in 390 patients. Successful PCI was achieved in a high percentage of CTOs with a low incidence of complications. At one-year follow-up, patients with successful PCI of a CTO had a significantly better clinical outcome than those, whose PCI was unsuccessful.

The results of the OAT study (Occluded Artery Trial) [Hochman J. et al., 2005] were published in 2006. This trial was designed to verify, if re-opening a totally occluded infarct related artery (IRA) 3 to 28 days after MI in asymptomatic patients could improve the clinical outcome respect to an aggressive medical therapy alone. Results showed that at 5-year follow-up, the primary endpoint of the study (death/

MI/congestive heart failure) occurred in 17.2% of patients in the percutaneous coronary intervention (PCI) arm versus 15.6% in the medical treatment arm ( $p=0.2$ ). Individual endpoints of the study were identical in both arms, with the exception of a higher rate of fatal and nonfatal MI in the PCI arm of the study ( $p=0.02$ ). Moreover, apart from a modest attenuation of left ventricular remodeling, PCI did not reduce clinical events. In fact, there was a trend toward excess reinfarction in the PCI arm, not driven by peri-procedural MI. Overall, these results have shown that the routine use of aggressive secondary prevention without revascularization might represent the preferred therapy for OAT-eligible patients [Hochman J. et al., 2005].

The OAT's substudies have also provided interesting results. One of these studies [Malek L. et al., 2009] has shown that after an MI, persistent total occlusion of the left anterior descending coronary artery (LAD) is associated with a worse prognosis coed with occlusion of other IRAs. However, PCI of occluded LAD >24 hours post MI in stable patients is not beneficial and may increase the risk of adverse events comparing to optimal medical treatment alone.

In another substudy (TOSCA), it has been demonstrated that despite many of the re-opened culprit vessels were still opened at 1-year follow-up, ejection fraction had not improved significantly.

It is likely that the OAT results deluded interventional cardiologists, who are supporters of the "patent artery hypothesis". Many aspects of the OAT study have been criticized, including low-risk study population, low rate of myocardial viability, low statistical power of results because of, in the control population, cardiac events were less than estimated.

Additional predictors of re-opening outcome have also been identified: cardiologist's experience, employed materials and techniques, presence of collaterals branch, length of CTO, linearity of vessels or size <3 mm, type of the involved coronary vessel [Stone G. et al., 1990; Ivanhoe R. et al., 1992; Maiello L. et al., 1992; Kinoshita I. et al., 1995; Tan K. et al., 1995; Moussa I. et al., 1998; Kahler J. et al., 2000; Noguchi T. et al., 2000; Dong S. et al., 2005; Dzavik V. et al., 2006].

From this data, it appears that revascularization of CTO should be reserved to a niche of patients, only in highly skilled laboratories, and that the medical, percutaneous or surgical treatment options should always be carefully taken into consideration and chosen on sound clinical ground.

On the basis of the above outlined concepts, indication to revascularization in patients with severe reduction of cardiac function should not be based solely on residual myocardial viability evaluation. More specifically, the European Society of Cardiology states [Underwood S. et al., 2004] that:

- detection of hibernation is most relevant in dyspnoea rather than angina symptoms;
- radionuclide perfusion imaging and dobutamine echocardiography have similar performance and the choice depends upon availability, local expertise and whether a more sensitive (radionuclide myocardial perfusion imaging) or a more specific technique (dobutamine echocardiography) is required for predicting recovery of LV function;
- PET or MRI should be used, if clarification is needed after echocardiography and/or radionu-

clide perfusion imaging; however, if readily available, PET scanning is an alternative initial test and MRI is an acceptable alternative to echocardiography, when assessment of LV function at rest and during stress is required. We also believe that in some cases plain stress ECG may be a useful tool.

The ACC/AHA guidelines (2009) for chronic heart failure and noninvasive imaging (with the exclusion of patients not eligible for revascularization of any kind) state [Hunt S. et al., 2005] that:

- non-invasive imaging to detect myocardial ischaemia and viability is reasonable in patients presenting with heart failure, who have known coronary artery disease and no angina unless the patient is not eligible for revascularization of any kind (Level of Evidence B);
- magnetic resonance imaging may be used to identify myocardial viability and scar tissue.

## REFERENCES

1. Abraham T.P., Nishimura R.A. Myocardial strain: can we finally measure contractility? J. Am. Coll. Cardiol. 2001; 37: 731-734.
2. Afridi I., Kleiman N.S., Raizner A.E., Zoghbi W.A. Dobutamine echocardiography in myocardial hibernation. Optimal dose and accuracy in predicting recovery of ventricular function after coronary angioplasty. Circulation. 1995; 91: 663-670.
3. Alderman E.L., Fisher L.D., Litwin P. et al. Results of coronary artery surgery in patients with poor left ventricular function (CASS). Circulation. 1983; 68: 785-795.
4. Anderson H.V., Shaw R.E., Brindis R.G. et al. A contemporary overview of percutaneous coronary interventions: the American College of Cardiology - National Cardiovascular Data Registry (ACC-NCDR). J. Am. Coll. Cardiol. 2002; 39: 1096-1103.
5. Arnese M., Cornel J.H., Salustri A., Maat A., Elhendy A., Reijs A.E., Ten Cate F.J., Keane D., Balk A.H., Roelandt J.R. Prediction of improvement of regional left ventricular function after surgical revascularization. A comparison of low-dose dobutamine echocardiography with 201-Tl single photon emission computed tomography. Circulation. 1995; 91: 2748-2752.
6. Baer F.M., Voth E., Deutsch H.J. et al. Predictive value of low dose dobutamine transesophageal echocardiography and fluorine-18 fluorodeoxyglucose positron emission tomography for recovery of regional left ventricular function after successful revascularization. J. Am. Coll. Cardiol. 1996; 28: 60.
7. Baumgartner H., Porenta G., Lau Y.-K., et al. Assessment of myocardial viability by dobutamine echocardiography, positron emission tomography and thallium-201 SPECT: Correlation with histopathology in explanted hearts. J. Am. Coll. Cardiol. 1998; 32: 1701-1708.
8. Bax J.J., Cornel J.H., Visser F.C., Fioretti P.M., van Lingen A., Reijs A.E., Boersma E., Teule G.J., Visser C.A. Prediction of recovery of myocardial dysfunction after revascularization. Comparison of fluorine-18 fluorodeoxyglucose-thallium-201 SPECT, thallium-201 stress-reinjection SPECT and dobutamine echocardiography. J. Am. Coll. Cardiol. 1996; 28: 558-564.
9. Bax J.J., Patton J.A., Poldermans D., Elhendy A., Sandler M.P. 18-Fluorodeoxyglucose imaging with positron emission tomography and single photon emission computed tomography: cardiac applications. Semin. Nucl. Med. 2000; 30: 281-298.

10. Bax J.J., Poldermans D., Elhendy A, Boersma E, Rahimtoola SH. Sensitivity, specificity, and predictive accuracies of various non invasive techniques for detecting hibernating myocardium. *Curr. Probl. Cardiol.* 2001; 26: 141-186.
11. Bax J.J., Poldermans D., Elhendy A., Cornel J.H., Boersma E., Rambaldi R., Roelandt J.R., Fioretti P.M. Improvement of left ventricular ejection fraction, heart failure symptoms and prognosis after revascularization in patients with chronic coronary artery disease and viable myocardium detected by dobutamine stress echocardiography. *J. Am. Coll. Cardiol.* 1999; 34:163-169.
12. Bax J.J., Schinkel A.F., Boersma E., Rizzello V., Elhendy A., Maat A., Roelandt J.R., van der Wall E.E., Poldermans D. Early versus delayed revascularization in patients with ischaemic cardiomyopathy and substantial viability: impact on outcome. *Circulation.* 2003; 108(Suppl. 1): 1139-1142.
13. Bax J.J., Wijns W., Cornel J.H., Visser H.C., Boersma E., Fioretti P.M. Accuracy of the currently available techniques for prediction of functional recovery after revascularization in patients with left ventricular dysfunction due to chronic coronary artery disease: comparison of pooled data. *J. Am. Coll. Cardiol.* 1997; 30: 1451-1460.
14. Beanlands R.S., Dawood F., Wen W.H., McLaughlin P.R., Butany J., D'Amati G., Liu P.P. Are the kinetics of technetium-99m methoxy-isobutyl isonitrile affected by cell metabolism and viability? *Circulation.* 1999; 82: 1802-1814.
15. Beanlands R.S., Hendry P.J., Masters R.G., deKemp R.A., Woodend K., Ruddy T.D. Delay in revascularization is associated with increased mortality rate in patients with severe left ventricular dysfunction and viable myocardium on fluorine 18-fluorodeoxyglucose positron emission tomography imaging. *Circulation.* 1998; 98: 1151-1156.
16. Ben-Haim S.A., Osadchy D., Schuster I., Gepstein L., Hayam G., Josephson M.E. Nonfluoroscopic, in vivo, navigation and mapping technology. *Nature Med.* 1996; 2: 1393-1395.
17. Bernhard L., Gerber B.L., Rochitte C.E., Bluemke D.A., Melin J.A., Crosille P., Becker L.C., Lima João A.C. Relation between Gd-DTPA contrast enhancement and regional inotropic response in the periphery and center of myocardial infarction. *Circulation.* 2001; 104: 998-1004.
18. Bisi G., Sciagra R., Santoro G.M., Fazzini P.F. Rest Technetium-99m sestamibi tomography in combination with short term administration of nitrates: feasibility and reliability for prediction of postrevascularization outcome of asynergic territories. *J. Am. Coll. Cardiol.* 1994; 24: 1282-1289.
19. Bourassa M., Lesperance J., Campeau L., Saltiel J. Fate of left ventricular contraction following aorto-coronary venous grafts: Early and late post-operative modifications. *Circulation.* 1972; 46: 724-730.
20. Braunwald E., Kloner R. A. The stunned myocardium: prolonged, postischemic ventricular dysfunction. *Circulation.* 1982; 66: 1146-1149.
21. Brunken R., Tillisch J., Schwaiger M., Child J.S., Marshall R., Mandelkern M., Phelps M.E., Schelbert H.R. Regional perfusion, glucose metabolism and wall motion in patients with chronic electrocardiographic Q wave infarctions: Evidence for persistence of viable tissue in some infarct regions by positron emission tomography. *Circulation.* 1986; 73: 951-963.
22. Cabin H.S., Clubb K.S., Vita N., Zaret B.L. Regional dysfunction by equilibrium radionuclide angiocardiology: A clinico-pathological study evaluating the relation of degree of dysfunction to the presence and extent of myocardial infarction. *J. Am. Coll. Cardiol.* 1987; 10: 743-747.
23. Chappuis F., Meier B., Belenger J., Blaeuenstein P., Lerch R. Early assessment of tissue viability with radioiodinated heptadecanoic acid in reperfused canine myocardium: Comparison with thallium-201. *Am. Heart J.* 1990; 119: 833-834.
24. Chatterjee K., Swan H.J.C., Parmley W.W., Sustaita H., Marcus H., Mattloff J. Depression of left ventricular function due to acute myocardial ischaemia and its reversal following aorto-coronary saphenous vein by-pass. *N. Engl. J. Med.* 1972; 286: 1117-1122.
25. Cornel J.H., Bax J.J., Elhendy A., Maat A.P., Kimman G.J., Geleijnse M.L., Rambaldi R., Boersma E., Fioretti P.M. Biphasic response to dobutamine predicts improvement of global left ventricular function after surgical revascularization in patients with stable coronary artery

- disease: implications of time course of recovery on diagnostic accuracy. *J. Am. Coll. Cardiol.* 1998; 31: 1002-1010.
26. Cwajg J.M., Cwajg E., Nagueh S.F., He Z.X., Qureshi U., Olmos L.I., Quinones M.A., Verani M.S., Winters W.L., Zoghbi W.A. End-diastolic wall thickness as a predictor of recovery of function in myocardial hibernation: relation to rest-redistribution Tl-201 tomography and dobutamine stress echocardiography. *J. Am. Coll. Cardiol.* 2000; 35: 1152-1161.
27. Desideri A., Cortigiani L., Christen A.I., Coscarelli S., Gregori D., Zanco P., Komorovsky R., Bax J.J. The extent of perfusion-F18-fluorodeoxyglucose positron emission tomography mismatch determines mortality in medically treated patients with chronic ischemic left ventricular dysfunction. *J. Am. Coll. Cardiol.* 2005; Oct 4; 46(7): 1264-1269.
28. Dilsizian V., Bonow R.O. Differential uptake and apparent 201Tl washout after thallium reinjection. Options regarding early redistribution imaging before reinjection or late redistribution imaging after reinjection. *Circulation.* 1992; 85: 1032.
29. Dong S., Smorgick Y., Nahir M. et al. Predictors for successful angioplasty of chronic totally occluded coronary arteries. *J. Interv. Cardiol.* 2005; 181: 1-7.
30. Dunn F.R., Bailey I.U., Kren R., Kelly D.T. Exercise-induced ST-segment elevation: Correlation of thallium 201 myocardial perfusion scanning and coronary arteriography. *Circulation.* 1980; 61: 989-995.
31. Dyke S.H., Cohn P.F., Gorlin R., Sonnenblick E.H. Detection of residual myocardial function in coronary artery disease using post-extra systolic potentiation. *Circulation.* 1974; 50: 694-699.
32. Dzavik V., Buller C.E., Lamas G.A. et al. Randomized Trial of Percutaneous Coronary Intervention for Subacute Infarct-Related Coronary Artery Occlusion to Achieve Long-Term Patency and Improve Ventricular Function: The Total Occlusion Study of Canada (TOSCA)-2 Trial. *Circulation.* 2006; 114: 2449-2457.
33. Eitzman D.V., Al-Aovar Z., Kanter H.L. Clinical outcome of patients with advanced coronary artery disease after viability studies with positron emission tomography. *J. Am. Coll. Cardiol.* 1992; 20(3): 559-565.
34. Elsässer A., Schlepfer M., Kleovekorn W.P. et al. Hibernating myocardium: an incomplete adaptation to ischemia. *Circulation.* 1997; 96: 2920-2931.
35. Falcone R.A., Marcovitz P.A., Perez J.E., Ditrach H.C., Hopkins W.E., Armstrong W.F. Intravenous albumin during dobutamine stress echocardiography: enhanced localization of left ventricular endocardial borders. *Am. Heart J.* 1995; 130: 254-258.
36. Faletta F., Crivellaro W., Pirelli S., Parodi O., De Chiara F., Cipriani M., Corno R., Pezzano A. Value of transthoracic two-dimensional echocardiography in predicting viability in patients with healed Q-wave anterior wall myocardial infarction. *Am. J. Cardiol.* 1995; 76: 1002-1006.
37. Fox K.M., Jonathan A., England D., Selwyn A.P. Significance of exercise-induced ST segment elevation in patients with previous myocardial infarction. *Am. J. Cardiol.* 1982; 49: 933-945.
38. Fragasso G., Chierchia S.L., Landoni C., Lucignani G., Rossetti E., Sciammarella M., Vanoli G.E., Fazio F. Regional glucose utilization in infarcted and remote myocardium: its relation to coronary anatomy and perfusion. *Nucl. Med. Commun.* 1998; 19: 625-632.
39. Fragasso G., Chierchia S.L., Lucignani G., Landoni C., Conversano A., Gilardi M.C., Colombo F., Rossetti C., Fazio F. Time dependence of residual tissue viability after myocardial infarction assessed by [<sup>18</sup>F] Fluorodeoxyglucose and positron emission tomography. *Am. J. Cardiol.* 1993a; 72: 131G-139G.
40. Fragasso G., Chierchia S.L., Pizzetti G., Dosio F., Fazio F. Reverse redistribution of thallium-201 heralding the development of myocardial infarction: description of two cases. *J. Nucl. Biol. Med.* 1994; Sep; 38(3): 515-517.
41. Fragasso G., Chierchia S.L., Rossetti E., Sciammarella M.G., Conversano A., Lucignani G., Landoni C., Calori G., Margonato A., Fazio F. Myocardial viability assessed with fluorodeoxyglucose and PET in patients with Q wave myocardial infarction receiving thrombolysis: relationship to

- coronary anatomy and ventricular function. Nucl. Med. Commun. 1997; 18:191-199.
42. *Fragasso G., Margonato A., Chierchia S.L.* Assessment of viability after myocardial infarction. Clinical relevance and methodological problems. Int. J. Card. Imaging. 1993; 9: 3-10.
43. *Franke A., Hoffmann R., Kuhl H.P., Lepper W., Breithardt O.A., Schormann M., Hanrath P.* Non-contrast second harmonic imaging improves interobserver agreement and accuracy of dobutamine stress echocardiography in patients with impaired image quality. Heart. 2000; 83: 133-140.
44. *Fudo T., Kambara H., Hashimoto M., Nohara R., Tamaki N., Yonekura Y., Senda M., Konishi J., Kawai C.* F-18-Deoxyglucose and stress N-13 ammonia positron emission tomography in anterior wall healed myocardial infarction. Am. J. Cardiol. 1988; 61: 1191-1197.
45. *Gepstein L., Hayam G., Ben-Haim S.A.* A novel method for nonfluoroscopic catheter-based electroanatomical mapping of the heart: In vitro and in vivo accuracy results. Circulation. 1997 a ; 95: 1611-1622.
46. *Gepstein L., Hayam G., Shpun S., Ben-Haim S.A.* Hemodynamic evaluation of the heart with a nonfluoroscopic electromechanical mapping technique. Circulation. 1997 b; 96: 3672-3680.
47. *Geskin G., Kramer C.M., Rogers W.J., Theobald T.M., Pakstis D., Hu Y.L., Reichel N.* Quantitative assessment of myocardial viability after infarction by dobutamine magnetic resonance tagging. Circulation. 1998; 98: 217-223.
48. *Gorcsan J. 3rd, Deswal A., Mankad S., Mandarino W.A., Mahler C.M., Yamazaki N., Katz W.E.* Quantification of the myocardial response to low-dose dobutamine using tissue Doppler echocardiographic measures of velocity and velocity gradient. Am. J. Cardiol. 1998; 81: 615-623.
49. *Götte M.J., van Rossum A.C., Twisk J.W.R., Kuijper J.P.A., Marcus J.T., Visser C.A.* Quantification of regional contractile function after infarction: strain analysis superior to wall thickening analysis in discriminating infarct from remote myocardium. J. Am. Coll. Cardiol. 2001; 37: 808-817.
50. *Gould K.L., Haynie M., Hess M.J., Yoshida K., Mullani N., Smalling R.W.* Myocardial metabolism of fluorodeoxyglucose compared to cell membrane integrity of the potassium analogue RB-82 for assessing infarct size in man by PET. J. Nucl. Med. 1991; 32: 1-9.
51. *Gropler R.J., Geltman E.M., Sampathkumaran K., Perez J.E., Conversano A., Sobel B.E., Bergmann S.R., Siegel B.A.* Comparison of carbon-11-acetate with fluorine-18-fluorodeoxyglucose for delineating viable myocardium by positron emission tomography. J. Am. Coll. Cardiol. 1993; 22: 1587-1597.
52. *Gunning M.G., Anagnostopoulos C., Knight C.J., Pepper J., Burman E.D., Davies G., Fox K.M., Pennell D.J., Ell D.J., Underwood S.R.* Comparison of 201Tl, 99mTc-tetrofosmin, and dobutamine magnetic resonance imaging for identifying hibernating myocardium. Circulation. 1998; 98: 1869-1874.
53. *Gyöngyösi M., Khorsand A., Sochor H., Sperker W., Strehlow C., Graf S., Binder T., Glogar D.* Characterization of hibernating myocardium with NOGA electroanatomic endocardial mapping. Am. J. Cardiol. 2000; 15; 95(6): 722-728.
54. *Hanekom L., Jenkin, C., Jeffries L. et al.* Incremental value of strain rate analysis as an adjunct to wall-motion scoring for assessment of myocardial viability by dobutamine echocardiography: a follow-up study after revascularization. Circulation. 2005; 112: 3892.
55. *Hernandez-Pampaloni M., Pearl V., Carreras J.L., Sanchez-Harguindey L., Vilacosta I.* Biphasic response to dobutamine predicts improvement of left ventricular dysfunction after revascularization: correlation with positron-emission and redistribution 201Tl tomographies. Int. J. Cardiovasc. Imaging. 2003; 19: 519-528.
56. *Hochman J.S., Choo H.* Limitation of myocardial infarct expansion by reperfusion independent of myocardial salvage. Circulation. 1987; 75: 299-306.
57. *Hochman J.S., Lamas G.A., Buller C.E., Dzavik V., Reynolds H.R., Abramsky S.J., Forman S., Ruzyllo W., Maggioni A.P., White H., Sadowski Z., Carvalho A.C., Rankin J.M., Renkin J.P., Steg P.G., Mascette A.M., Sopko G., Pfisterer M.E., Leor J., Fridrich V., Mark D.B., Knatterud G.L.* Coronary

- Intervention for Persistent Occlusion after Myocardial Infarction. *The New England Journal of Medicine*. 2006; 355: 2395-2407.
58. Hochman J.S., Lamas G.A., Knatterud G.L., Buller C.E., Dzavik V., Mark D.B., Reynolds H.R., White H.D. Occluded Artery Trial Research Group. Design and methodology of the Occluded Artery Trial (OAT). *Am. Heart J.* 2005; 150: 627-642.
59. Hoffmann U., Millea R., Finzweiler C., Ferencik M., Gulick S., Titus J., Achenbach S., Kwait D., Sosnovik D., Brady T.J. Acute myocardial infarction: contrast-enhanced multidetector row CT in a porcine model. *Radiology*. 2004; 231(3): 697-701.
60. Horie H., Takahashi M., Minai K., Izumi M., Takaoka A., Nozawa M., Yokohama H., Fujita T., Sakamoto T., Kito O., Okamura H., Kinoshita M. Long-term beneficial effect of late reperfusion for acute anterior myocardial infarction with percutaneous transluminal coronary angioplasty. *Circulation*. 1998; 98: 2377-2382.
61. Horn H.R., Teichholtz L.E., Cohn P.F., Herman M.V., Gorlin R. Augmentation of left ventricular contraction in coronary artery disease by an inotropic catecholamine: The epinephrine ventriculogram. *Circulation*. 1974; 49: 1063-1071.
62. Hunt S.A., Abraham W.T., Chin M.H. et al. ACC/AHA 2005 Guideline Update for the Diagnosis and Management of Chronic Heart Failure in the Adult: a report of the American College of Cardiology/American Heart Association Task Force on Practice Guidelines (Writing Committee to Update the 2001 Guidelines for the Evaluation and Management of Heart Failure): developed in collaboration with the American College of Chest Physicians and the International Society for Heart and Lung Transplantation: endorsed by the Heart Rhythm Society. *Circulation*. 2005; 112: e154.
63. Ibrahim R., Bülow H.P., Hackl T., Hörnke M., Nekolla S.G., Breuer M., Schömig A., Schwaiger M. Diagnostic value of contrast-enhanced magnetic resonance imaging and single-photon emission computer tomography for detection of myocardial necrosis early after acute myocardial infarction. *J. Am. Coll. Cardiol.* 2007; 49(2): 208-216.
64. Ichikawa Y., Sakuma H., Suzawa N., et al. Late gadolinium-enhanced magnetic resonance imaging in acute and chronic myocardial infarction: improved prediction of regional myocardial contraction in the chronic state by measuring thickness of nonenhanced myocardium. *J. Am. Coll. Cardiol.* 2005; 45: 901.
65. Ivanhoe R.J., Weintraub W.S., Douglas J.R. Jr. et al. Percutaneous transluminal coronary angioplasty of chronic total occlusions. Primary success, restenosis, and long-term clinical follow-up. *Circulation*. 1992; 85: 106-115.
66. Kaandorp T.A., Lamb H.J., van der Wall E.E., de Roos A., Bax J.J. Cardiovascular MR to assess myocardial viability in chronic ischaemic LV dysfunction. *Heart*. 2005; 91(10): 1359-1365.
67. Kahler J., Koster R., Brockhoff C. et al. Initial experience with a hydrophilic-coated guidewire for recanalization of chronic total coronary occlusions. *Catheter Cardiovasc. Interv.* 2000; 49: 45-50.
68. Kasprzak J.D., Paelinck B., Ten Cate F.J., Vletter W.B., de Jong N., Poldermans D., Elhendy A., Bouakaz A., Roelandt J.R. Comparison of native and contrast-enhanced harmonic echocardiography for visualization of left ventricular endocardial border. *Am. J. Cardiol.* 1999; 83: 211-217.
69. Kim R.J., Fieno D.S., Parrish T.B. et al. Relationship of MRI delayed contrast enhancement to irreversible injury, infarct age, and contractile function. *Circulation*. 1999; 100: 1992-2002.
70. Kinoshita I., Katoh O., Nariyama J. et al. Coronary angioplasty of chronic total occlusions with bridging collateral vessels: immediate and follow-up outcome from a large single-center experience. *J. Am. Coll. Cardiol.* 1995; 26: 409-415.
71. Klein C., Nekolla S.G., Bengel F.M., Momose M., Sammer A., Haas F., Schnackenburg B., Delius W., Mudra H., Wolfram D., Schwaiger M. Assessment of myocardial viability with contrast-enhanced magnetic resonance imaging: comparison with positron emission tomography. *Circulation*. 2002; 105(2): 162-167.
72. Klein M.D., Herman M.V., Gorlin R. A hemodynamic study of left ventricular aneurysm. *Circulation*. 1967; 35: 614-630.

73. Kuhl H.P., Beek A. M., van der Weerd A. P., Hofman M.B.M., Visse C. A., Lammertsma A.A., Heussen N., Visser F. C., van Rossum A. C. Myocardial viability in chronic ischemic heart disease comparison of contrast-enhanced magnetic resonance imaging with (18)-F-fluorodeoxyglucose positron emission tomography. *J. Am. Coll. Cardiol.* 2003; 41(8): 1341-1348.
74. La Canna G., Rahimtoola S.H., Visioli O., Giubbini R., Alfieri O., Zognio M., Milan E., Ceconi C., Gargano M., Lo Russo R., Ferrari R. Sensitivity, specificity, and predictive accuracies of non-invasive tests, singly and in combination, for diagnosis of hibernating myocardium. *Eur. Heart J.* 2000; 21: 1358-1367.
75. Lamas G.A., Pfeffer M.A. Increased left ventricular volume following myocardial infarction in man. *Am. Heart J.* 1986; 111: 30-35.
76. Lardo A.C., Cordeiro M.A., Silva C., Amado L.C., George R.T., Saliaris A.P., Schuleri K.H., Fernandes V.R., Zviman M., Nazarian S., Halperin H.R., Wu K.C., Hare J.M., Lima J.A. Contrast-enhanced multidetector computed tomography viability imaging after myocardial infarction: characterization of myocyte death, microvascular obstruction, and chronic scar. *Circulation.* 2006; 113(3): 394-404.
77. Lee K.S., Marwick T.H., Cook S.A., Go R.T., Fix J.S., James K.B., Sapp S.K., MacIntyre W.J., Thomas J.D. Prognosis of patients with left ventricular dysfunction, with and without viable myocardium after myocardial infarction. Relative efficacy of medical therapy and revascularization. *Circulation.* 1994; 90: 2687-2697.
78. Lessick J. Electromechanical mapping of regional left ventricular function in humans: comparison with echocardiography. *Cath. Cardiovasc. Interv.* 2000; 50: 10-18
79. Leung W.H., Lau C.P. Effects of severity of the residual stenosis of the infarct-related coronary artery on left ventricular dilation and function after acute myocardial infarction. *J. Am. Coll. Cardiol.* 1992; 20: 307-313.
80. Lu C., Carlino M., Fragasso G., Maisano F., Cappelletti A., Margonato M., Chierchia S.L. Enoximone echocardiography for prediction of recovery of left ventricular dysfunction after revascularization: a novel test for detecting myocardial viability. *Circulation.* 2000; 101: 1255-1260.
81. Lu F., Carlino M., Lu C., Landoni C., Lucignani G., Fragasso G., Bello V.D., Margonato A., Chierchia S.L., Marzilli M., Balbarini A. Assessment of Residual Viability by Enoximone Echocardiography in Patients with Previous Myocardial Infarction Correlation with Positron Emission Tomographic Studies and Functional Follow-Up. *Echocardiography.* March 2010. *EPub ahead of print.*
82. Maiello L., Colombo A., Gianrossi R. et al. Coronary angioplasty of chronic occlusions: factors predictive of procedural success. *Am. Heart J.* 1992; 124: 581-584.
83. Malek L.A., Reynolds H.R., Forman S.A., Vozzi C., Mancini G.B., French J.K., Dziarmaga M., Renkin J.P., Kochman J., Lamas G.A., Hochman J.S. Late coronary intervention for totally occluded left anterior descending coronary arteries in stable patients after myocardial infarction: Results from the Occluded Artery Trial (OAT). *Am. Heart J.* 2009; 157(4): 724-732.
84. Margonato A., Ballarotto C., Bonetti F., Cappelletti A., Sciammarella M., Cianflone D., Chierchia S.L. Assessment of residual tissue viability by exercise testing in recent myocardial infarction: comparison of the electrocardiogram and myocardial perfusion scintigraphy. *J. Am. Coll. Cardiol.* 1992;19: 948-952.
85. Margonato A., Chierchia S.L., Xuereb R.G., Xuereb M., Fragasso G., Cappelletti A., Landoni C., Lucignani G., Fazio F. Specificity and sensitivity of exercise-induced ST segment elevation for detection of residual viability: comparison with fluorodeoxyglucose and positron emission tomography. *J. Am. Coll. Cardiol.* 1995; 25:1032-1038.
86. Margonato A., Mailhac A., Bonetti F., Vicedomini G., Fragasso G., Landoni C., Lucignani G., Rossetti C., Fazio F., Chierchia S.L. Exercise-induced ischemic arrhythmias in patients with previous myocardial infarction: role of perfusion and tissue viability. *J. Am. Coll. Cardiol.* 1996; Mar 1; 27(3): 593-598.
87. Marin-Neto J.A., Dilsizian V., Arrighi J.A., Perone-Filardi P., Bacharach S.L., Bonow R.O.

- Thallium scintigraphy compared with 18F-fluorodeoxyglucose positron emission tomography for assessing myocardial viability in patients with moderate versus severe left ventricular dysfunction. *Am. J. Cardiol.* 1998; 82: 1001-1011.
88. *Moussa I., Di Mario C., Moses J. et al.* Comparison of angiographic and clinical outcomes of coronary stenting of coronary total occlusions versus subtotal occlusions. *Am. J. Cardiol.* 1998; 81: 1-6.
89. *Murray G., Schad N., Ladd W., Allie D., van der Zwagg R., Avet P., Rockett J.* Metabolic cardiac imaging in severe coronary disease: Assessment of viability with iodine-123-iodophenylpentadecanoic acid and multicrystal gamma camera, and correlation with biopsy. *J. Nucl. Med.* 1992; 33: 1269-1277.
90. *Nagueh S.F., Vaduganathan P., Ali N., Blaustein A., Verani M.S., Winters W.L., Jr., Zoghbi W.A.* Identification of hibernating myocardium: comparative accuracy of myocardial contrast echocardiography, rest-redistribution thallium-201 tomography and dobutamine echocardiography. *J. Am. Coll. Cardiol.* 1997; 29: 985-993.
91. *Noguchi T., Miyazaki M.S., Morii I. et al.* Percutaneous transluminal coronary angioplasty of chronic total occlusions. Determinants of primary success and long-term clinical outcome. *Catheter Cardiovasc. Interv.* 2000; 49: 258-264.
92. *Olivari Z., Rubartelli P., Piscione F., Etti F., Fontanelli A., Salemme L., Giachero C., Di Mario C., Gabrielli G., Spedicato L., Bedogni F.* TOAST-GISE Investigators. Immediate results and one-year clinical outcome after percutaneous coronary interventions in chronic total occlusions: data from a multicenter, prospective, observational study (TOAST-GISE). *J. Am. Coll. Cardiol.* 2003 May 21; 41(10): 1672-1678.
93. *Pagano D., Bonser R.S., Townend J.N., Ordoubadi F., Lorenzoni R., Camici P.G.* Predictive value of dobutamine echocardiography and positron emission tomography in identifying hibernating myocardium in patients with postischemic heart failure. *Heart.* 1998; 79: 281-288.
94. *Paul J.F., Wartski M., Caussin C., Sigal-Cinquandre A., Lancelin B., Angel C., Dambrin G.* Late defect on delayed contrast-enhanced multidetector row CT scans in the prediction of SPECT infarct size after reperfused acute myocardial infarction: initial experience. *Radiology.* 2005; 236(2): 485-489.
95. *Pfeffer M.A., Braunwald E.* Ventricular remodeling after myocardial infarction: experimental observations and clinical implications. *Circulation.* 1990; 81: 1161-1172.
96. *Pizzetti G., Belotti G., Margonato A., Cappellotti A., Chierchia S.* Coronary recanalization by elective angioplasty prevents ventricular dilation after anterior myocardial infarction. *J. Am. Coll. Cardiol.* 1996; 28: 837-845.
97. *Porter T.R., Xie F., Kricsfeld A., Chiou A., Dabestani A.* Improved endocardial border resolution during dobutamine stress echocardiography with intravenous sonicated dextrose albumin. *J. Am. Coll. Cardiol.* 1994; 23: 1440-1443.
98. *Rahimtoola S.H.* A perspective on the three large multicenter randomized clinical trials of coronary bypass surgery for chronic stable angina. *Circulation.* 1985; 72 (suppl V): 123-135.
99. *Rahimtoola S.H.* Coronary bypass surgery for chronic angina – 1981. A perspective. *Circulation.* 1982; 65: 225-241.
100. *Rahimtoola S.H.* The hibernating myocardium. *Am. Heart J.* 1989; 117: 211-222.
101. *Ratib O., Phelps M.E., Huang S.C., Henze E., Selin C.E., Schelbert H.R.* Positron tomography with deoxyglucose for estimating local myocardial glucose metabolism. *J. Nucl. Med.* 1982; 23: 577-586.
102. *Rizzello V., Bax J.J., Schinkel A.F., Boersma E., Bountiokos M., Vourvouri E.C., Crea F., Biagini E., Elhendy A., Roelandt J.R., Poldermans D.* Does resting two dimensional echocardiography identify patients with ischaemic cardiomyopathy and low likelihood of functional recovery after coronary revascularization? *Coron. Artery Dis.* 2004; 15: 269-275.
103. *Rizzello V., Schinkel A.F., Bax J.J., Boersma E., Bountiokos M., Vourvouri E.C., Krenning B., Agricola E., Roelandt J.R., Poldermans D.* Individual prediction of functional recovery after coronary revascularization in patients with ischaemic cardiomyopathy: the scar- to-biphasic model. *Am. J. Cardiol.* 2003; 91: 1406-1409.

104. Rozanski A., Berman D., Gray R., Diamond G., Raymond M., Prause J.A., Maddahi J., Swan H.J., Matloff J. Preoperative prediction of reversible myocardial asynergy by post-exercise radionuclide ventriculography. *N. Eng. J. Med.* 1982; 307: 212-216.
105. Sawada S., Bapat A., Vaz D., Weksler J., Fineberg N., Greene A., Gradus-Pizlo I., Feigenbaum H. Incremental value of myocardial viability for prediction of long-term prognosis in surgically revascularized patients with left ventricular dysfunction. *J. Am. Coll. Cardiol.* 2003; 42: 2099-2105.
106. Schinkel A.F., Poldermans D., Elhendy A., Bax J.J. Assessment of myocardial viability in patients with heart failure. *J. Nucl. Med.* 2007 Jul; 48(7):1135-1146. Epub 2007 Jun 15.
107. Sciagra R., Bisi G., Santoro G.M., Zeraushek F., Sestini S., Pedenovi P., Pappagallo R., Fazzini P.F. Comparison of baseline-nitrate technetium-99m sestamibi with rest-redistribution thallium-201 tomography in detecting viable hibernating myocardium and predicting post revascularization recovery. *J. Am. Coll. Cardiol.* 1997; 30: 384-391.
108. Selvanayagam J.B., Jerosch-Herold M., Porto I. et al. Resting myocardial blood flow is impaired in hibernating myocardium; a magnetic resonance study of quantitative perfusion assessment. *Circulation.* 2005; 112: 3289-3296.
109. Selvanayagam J.B., Kardos A., Francis J.M. et al. Value of delayed-enhancement cardiovascular magnetic resonance imaging in predicting myocardial viability after surgical revascularization. *Circulation.* 2004; 110: 1535-1541.
110. Sheiban I., Fragasso G., Rosano G.M., Dharmadhikari A., Tzifos V., Pagnotta P., Chierchia S.L., Trevi G. Time course and determinants of left ventricular function recovery after primary angioplasty in patients with acute myocardial infarction. *J. Am. Coll. Cardiol.* 2001; 38: 464-471.
111. Siebelink H.M., Blanksma P.K., Crijns H.J., Bax J.J., van Boven A.J., Kingma T., Piers D.A., Pruijm J., Jager P.L., Vaalburg W., van der Wall E.E. No difference in cardiac event-free survival between positron emission tomography-guided and single-photon emission computed tomography-guided patient management: a prospective, randomized comparison of patients with suspicion of jeopardized myocardium. *J. Am. Coll. Cardiol.* 2001; 37: 81-88.
112. Smeets J.L., Ben-Haim S.A., Rodriguez L.M., Timmermans C., Wellens H.J. New method for nonfluoroscopic endocardial mapping in humans: accuracy assessment and first clinical results. *Circulation* 1998; 97: 2426-2432.
113. Sozzi F.B., Poldermans D., Boersma E., Elhendy A., Bax J.J., Borghetti A., Roelandt J.R. Does second harmonic imaging improve left ventricular endocardial border identification at higher rates during dobutamine stress echocardiography? *J. Am. Soc. Echocardiogr.* 2000; 13: 1019-1024.
114. Stiles G.L., Rosati R.A., Wallace A.G. Clinical relevance of exercise-induced ST segment elevation. *Am. J. Cardiol.* 1980; 46: 931-936.
115. Stone G.W., Rutherford B.D., Mc Conahay D.R. et al. Procedural outcome of angioplasty for total coronary artery occlusions: an analysis of 971 lesions in 905 patients. *J. Am. Coll. Cardiol.* 1990; 15: 849-856.
116. Suero J.A., Marso S.P., Jones P.G., Laster S.B., Huber K.C., Giorgi L.V., Johnson W.L., Rutherford B.D. Procedural outcomes and long-term survival among patient undergoing percutaneous coronary intervention of a chronic total occlusion in native coronary arteries: a 20-year experience. *J. Am. Coll. Cardiol.* 2001; 38(2): 409-414.
117. Tamaki N., Kawamoto M., Takahashi N., Yonekura Y., Magata Y., Nohara R., Kambara H., Sasayama S., Hirata K., Ban T. et al. Prognostic value of an increase in fluorine-18 deoxyglucose uptake in patients with myocardial infarction comparison with stress thallium imaging. *J. Am. Coll. Cardiol.* 1993; 22(6): 1621-1627.
118. Tamaki N., Kawamoto M., Yonekura Y., Fujibayashi Y., Takahashi N., Konishi J., Nohara R., Kambara H., Kawai C., Ikekubo H. Regional metabolic abnormality in relation to perfusion and wall motion in patients with myocardial infarction: Assessment with emission tomography using an iodinated branched fatty acid analog. *J. Nucl. Med.* 1992; 33: 659-667.
119. Tamaki N., Kawamoto M., Tadamura E., Magata Y., Yonekura Y., Nohara R., Sasayama S., Nishimura K., Ban T., Konishi J. Prediction of reversible ischemia after revascularization. Perfusion and metabolic studies with positron emission tomography. *Circulation.* 1995; 91:1697-1705.

120. Tan K., Sulke N., Taub B., Sowton E. Clinical and lesion morphologic determinants of coronary angioplasty success and complications. Current experience. *J. Am. Coll. Cardiol.* 1995; 25: 855-865.
121. Tillisch J., Brunken R., Marshall R., Schwaiger M., Mandelkern M., Phelps M., Schelbert H. Reversibility of cardiac wall motion abnormalities predicted by positron tomography. *N. Engl. J. Med.* 1986; 314: 884-888.
122. Tsutsui H., Uematsu M., Shimizu H., Yamagishi M., Tanaka N., Matsuda H., Miyatake K. Comparative usefulness of myocardial velocity gradient in detecting ischaemic myocardium by a dobutamine challenge. *J. Am. Coll. Cardiol.* 1998; 31: 89-93.
123. Underwood S.R., Bax J.J., vom Dahl J. et al. Imaging techniques for the assessment of myocardial hibernation. Report of a Study Group of the European Society of Cardiology. *Eur. Heart J.* 2004; 25: 815-836.
124. Van Eck-Smit B.L., van der Wall E.E., Kuijper A.F., Zwinderman A.H., Pauwels E.K. Immediate thallium-201 reinjection following stress imaging: a time saving approach for detection of myocardial viability. *J. Nucl. Med.* 1993; 34:737-743.
125. Vanoverschelde J.L., D'Hondt A.M., Marwick T., Gerber B.L., De Kock M., Dion R., Wijns W., Melin J.A. Head to head comparison of exercise-redistribution-reinjection thallium single-photon emission computed tomography and low dose dobutamine echocardiography for prediction of reversibility of chronic left ventricular ischaemic dysfunction. *J. Am. Coll. Cardiol.* 1996; 28: 432-442.
126. Vanoverschelde J.L., Gerber B.L., D'Hondt A.M., De Kock M., Dion R., Wijns W., Melin J.A. Pre-operative selection of patients with severely impaired left ventricular function for coronary revascularization. Role of low dose dobutamine echocardiography and exercise-redistribution-reinjection thallium SPECT. *Circulation.* 1995; 92: 1137-1144.
127. Visser F.C., van Eenige M.J., Westera G., Den Hollander W., Duwel C.M.B., Van der Wall E.E., Heidendal G.A., Roos J.P. Metabolic fate of radioiodinated heptadecanoic acid in the normal canine heart. *Circulation.* 1985; 72: 565-571.
128. Wagner A., Mahroholdt H., Holly T.A., Elliott M.D., Regenfus M., Parker M., Klocke F.J., Bonow R.O., Kim R.J., Judd R.M. Contrast-enhanced MRI and routine single photon emission computed tomography (SPECT) perfusion imaging for detection of subendocardial myocardial infarcts. An imaging study. *Lancet.* 2003; 361(9355): 374-379.
129. Weich H.F., Strauss H.W., Pitt B. The extraction of thallium-201 by the myocardium. *Circulation.* 1977; 56: 188-191.
130. Wellnhofer E., Olariu A., Klein C., Gräfe M., Wahl A., Fleck E., Nagel E. Magnetic resonance low-dose dobutamine test is superior to SCAR quantification for the prediction of functional recovery. *Circulation.* 2004; 109: 2172-2174.
131. Wiggers H., Botker H.E., Sogaard P. et al. Electromechanical mapping versus positron emission tomography and single photon emission computed tomography for the detection of myocardial viability in patients with ischemic cardiomyopathy. *J. Am. Coll. Cardiol.* 2003; 41: 843.
132. Yamaguchi A., Ino T., Adachi H., Mizuhara S., Kamio H. Left ventricular end-systolic volume index in patients with ischaemic cardiomyopathy predicts postoperative ventricular function. *Ann. Thorac. Surg.* 1995; 60: 1059-1062.
133. Yamamoto Y., De Silva R., Rhodes C.G., Arajuo L.I., Iida H., Rechavia E., Nihoyannopoulos P., Hackett D., Galassi A.R., Taylor C.J. A new strategy for the assessment of viable myocardium and regional myocardial blood flow using <sup>15</sup>O-water and dynamic positron emission tomography. *Circulation.* 1992; 86: 167-178.
134. Zamorano J., Wallbridge D.R., Ge J., Drozd J., Nesser J., Erbel R. Non-invasive assessment of cardiac physiology by tissue Doppler echocardiography. A comparison with invasive haemodynamics. *Eur. Heart J.* 1997; 18: 330-339.