

CASE REPORT**TORIC INTRAOCULAR LENS IMPLANTATION AND LIMBAL RELAXING INCISIONS IN CASE OF SURGICALLY INDUCED HIGH ASTIGMATISM: COMPLICATED CATARACT SURGERY****ZILFYAN A.A. *, HARUTYUNYAN S.L.**

"Shengavit" Medical Center, Yerevan, Armenia

*Received 10/15/2013; accepted in final form 12/10/2013***ABSTRACT**

In patients suffering from cataract and astigmatism it is preferable to use the method of phacoemulsification with toric intraocular lens implantation.

Patient A.A. presented to "Shengavit" Medical Center with low and blurred vision of the left eye, lack of binocular vision, diplopia, which forced him to close the left eye. The left eye visual acuity was 0.09 with correction sph (-)2.75, cyl(-) 8.0 ax 160 = 0.3; intraocular pressure made 10 mm Hg. The patient previously underwent a trabeculectomy with basal iridectomy because of primary open-angle glaucoma I-b.

In order to improve the eyesight function and correct the induced high astigmatism the left eye surgery has been applied: phacoemulsification using "Legacy Everest" ("Alcon", USA) with toric intraocular lens implantation and limbal relaxing incisions.

Based on data obtained it has been revealed that phacoemulsification with toric intraocular lens implantation and limbal relaxing incisions application for a patient with cataract and high induced astigmatism are the most preferred methods, which can improve both visual functions and the topography of the cornea in patients with the specified eye impairment.

KEYWORDS: *astigmatism, intraocular lens, limbal incisions.***INTRODUCTION**

Regardless of the development in ophthalmic surgery technologies, post surgery induced astigmatism is still a major problem in ophthalmology. Current methods of astigmatism correction do not always allow to treat the high induced astigmatism; hence, in some cases, in order to get good results, it is necessary to combine various methods and procedures. However, in cases with patients suffering from cataract and astigmatism, it is preferable to use the method of phacoemulsification with toric intraocular lens (IOL) implantation (Pershin K., Pasinova N., 2004 a,b). Although tra-

beculectomy is a gold standard in glaucoma surgery, in some cases refractive rehabilitation of patients is not always predictable. This is due to the fact that sometimes, though not frequent, an uncontrollable suture tension and its further shred can take place during suture adaptation of the scleral flap; this latter can further lead to a change of cornea shape in the form of with-the-rule or against-the-rule astigmatism.

The article presents a case of complicated cataract surgical management.

A patient with surgically induced high astigmatism was operated at "Shengavit" Medical Center using micro-coaxial phacoemulsification with posterior chamber IOL implantation and limbal relaxing incisions (LRI) (Maloney W., 1990; Miller K., 1997).

ADDRESS FOR CORRESPONDENCE:

"Shengavit" Medical Center
9 Manandyan Street, Yerevan, 0006, Armenia
Tel.: (37 410) 445 013
E-mail: zil.art@mail.ru

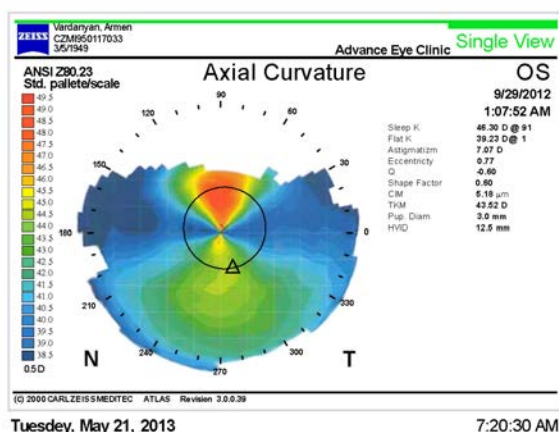


FIGURE 1. Patient A.A. Left eye image: keratotopography of the eye before surgery.

MATERIAL AND METHODS

Patient A.A. presented to “Shengavit” Medical Center with low and blurred vision of the left eye, lack of binocular vision, diplopia, which forced him to close the left eye. The left eye visual acuity was 0.09 with correction sph (-)2.75, cyl(-) 8.0 ax 160 = 0.3; intraocular pressure (IOP) made 10 mm Hg. The patient previously underwent a trabeculectomy with basal iridectomy because of primary open-angle glaucoma I-b. A biomicroscopy examination of the eye showed a cystic conjunctival filtration pad with insufficient scleral flap, transparent cornea, anterior chamber of medium depth, iris subathrophic, posterior *synechiae* and lens with opacity in all layers (++ by Burato). The results of autorefkeratometry performed on “Auto Ref-Keratometer” (“Tomey”, Japan) were as follows: 176° -39.80 dioptres (D), 86° -47.20 D, astigmatism -7.40 D (Figure 1).

In order to improve the eyesight function and correct the induced high astigmatism the left eye surgery has been applied: phacoemulsification using “Legacy Everest” (“Alcon”, USA) with toric IOL implantation and LRI. Intraocular toric lens was calculated using “AcrySof Toric IOL” online calculator (“Alcon”, USA), and the LRI was calculated using online “AMO LRI” calculator (“Abbott Medical Optics LRI Calculator”, USA) by means of NAPA alignment chart.

Temporal corneal tunnel incision was made, as a more preferable compared to the vertical one [Roman S. et al., 1998]. According to literature data,

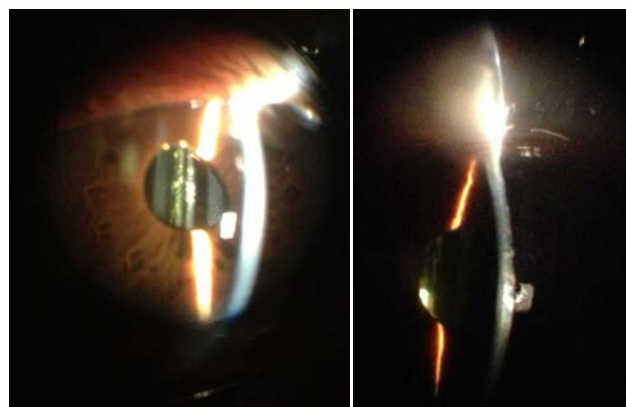


FIGURE 2. Patient A.A. Left eye image at the second postoperative day examination: a) with insufficient scleral flap and cystic conjunctival filtration pad; b) pseudophakic eye.

using temporal tunnel incisions brings to fast visual and refractive recovery [Kohnen T. et al., 1995]. A 24 D “AcrySof IQ Toric SN6AT9” lens (“Alcon”, USA) has been implanted with cylindrical power of 6.0 D, because this type IOL has more predictable design compared with other toric IOLs [Linnola R. et al., 1999; Guttman C., 2006]. Two 60° cornea incisions were done at relevant meridians.

RESULTS

Early postoperative period was smooth; no complications were registered. On the second day, after medicamentous pupil dilatation, the location of the IOL was evaluated. The IOL location was correct, condition of incisions – satisfactory, edges – clear. Left eye visual acuity was 1.0; IOP made 10 mm Hg. Binocular vision recovered, no asthenopic complaints were registered. The appropriate generally accepted treatment scheme was indicated. Further patient examinations were scheduled on the second day, in one week, one month and three months after the surgery (Figure 2).

CONCLUSION

Based on obtained data it has been revealed that phacoemulsification with toric IOL implantation and LRI application for a patient with cataract and high induced astigmatism are the most preferred methods, which can improve both visual functions and the topography of the cornea in patients with the specified eye impairment.

REFERENCES

1. *Guttman C.* Coaxial 2.2 mm microphaco technique reduces surgically induced astigmatism in study. *Ophthalmology Times*. 2006; 31: 46-47.
 2. *Kohnen T., Dick B., Jacobi K.W.* Comparison of the induced astigmatism after temporal clear corneal tunnel incisions of different sizes. *J. Cataract Refract. Surg.* 1995; 21(4): 417-424.
 3. *Linnola R.J., Sund M., Ylonen R., Pihlajaniemi T.* Adhesion of soluble fibronectin, laminin, and collagen type IV to intraocular lens materials. *J. Cataract Refract. Surg.* 1999; 25: 1486-1491.
 4. *Maloney W.F.* Astigmatic keratotomy to correct preexisting astigmatism in cataract patients. *J. Cataract Refract. Surg.* 1990; 16(3): 297-303.
 5. *Miller K.M.* Limbal arcuate keratotomy reduces up to 3 D of astigmatism. *Ocular surgery news*. 1997; 15(21): 24.
 6. *Pershin K.B., Pasinova N.F.* Features and capabilities of modern phacoemulsification. "Modern technology of cataract surgery – 2004": Collection of scientific articles. Moscow. 2004 a. P. 248-253.
 7. *Pershin K.B., Pasinova N.F.* Injection implantation, rather for than against. "Modern technology of cataract surgery – 2004": Collection of scientific articles. Moscow. 2004 b. P. 253-256.
 8. *Roman S.J., Auclin F.X., Chong-Sit D.A., Ullern M.M.* Surgically induced astigmatism with superior and temporal incisions in cases of with-the-rule preoperative astigmatism. *J. Cataract Refract. Surg.* 1998; 24: 1636-1641
-
-
-