



**PERIODONTAL LIGAMENT SENSORY APPARATUS:  
MORPHOLOGICAL AND FUNCTIONAL CHARACTERISTICS AND  
REACTION TO RESTORATION PROCEDURES USING SINGLE  
AND BLOCK PROSTHETIC APPLIANCES**

**Sanosyan G.V.<sup>1</sup>, Hovhannisyan S.R.<sup>2</sup>, Torgomyan A.L.<sup>3\*</sup>**

<sup>1</sup> Moscow State Medicine and Dentistry University, Moscow, Russia

<sup>2</sup> Prosthodontics Department, Yerevan State Medical University, Yerevan, Armenia,

<sup>3</sup> Normal Physiology Department, Yerevan State Medical University, Yerevan, Armenia

**Abstract**

*The aim of this study was to investigate peculiarities of nerve terminations and their distribution in the periodontal ligament of human teeth different groups, as well as the reaction of frontal teeth periodontal ligament sensory apparatus to restoration procedures using single and block prosthetic appliances. The study was done using the "Periosensomer" device. The morphological research of the tooth periodontal ligament revealed that it has well developed, compound sensory apparatus. All receptors of human periodontal ligament belong to the group of free nerve endings. The greater part of them has coiled or tree-like shape. The investigation on functional condition of periodontal ligament sensory apparatus revealed that at food holding phase the least forces are recorded when the jaw finds optimal position. Testing of food position and its consistence takes place during food holding by antagonist teeth. Further changes in jaw position are provided by sensitivity of periodontal ligament receptors. Estimating periodontal ligament sensory function and sensory reaction dynamics during food holding and splitting phase can be introduced as a method for functional diagnosis in prosthetic dentistry.*

**Keywords:** tooth, periodontal ligament, nerve endings, "Periosensomer" device s, sensory function.

**INTRODUCTION**

The periodontal ligament is a group of specific connective tissue fibers that essentially joins a tooth to the alveolar bone within which it located. It also serves as periosteum to the alveolar bone and furnishes a firm connection between the root of tooth and the bone through transitional fibrous networks. It consists, in part, of thick collagenous bundles that run from the alveolar wall to the cementum. The orientation of the fibers varies at different levels in the alveolus. From root apex up to neck, there are the cemento-alveolar fibers known as apical, oblique or horizontal, and alveolar crest fibers. These terms describe their direction or their attachments. The fiber bundles of the periodontal ligament have a little wavy direction. When the root is not functioning,

they are relaxed and allow it to move slightly upon stress. The ligament bordering to the cementum contains only cementoblasts and the usual set of connective tissue cells. On the alveolar bone surface of periodontal ligament, osteoblasts and osteoclasts may be found [Kanzaki H. et al., 2002; Adachi T., et al., 2003; Crotti T. et al., 2003]. Spread in many places in the periodontal ligament, especially near the surface of cementum, there are blood and lymph vessels and nerves embedded in a small amount of loose connective tissue, and small islands of epithelium. The epithelial rests commonly degenerate and undergo calcification [Van Driel W. et al., 2000].

The periodontal ligament varies in width from 0.15 to 0.4 mm. It provides support and continuance of the dentition and alveolar bone [Cahill D., 1969]. At the neck of tooth above the alveolar crest, the periodontal ligament joins the gingival connective tissue. At the root apex, the periodontal ligament merges with the pulp. The periodontal ligament con-

**Address for Correspondence:**

Yerevan State Medical University  
2 Koryun Street, 0025, Yerevan, Armenia  
Tel.: (+374 99) 557424  
E-mail: [adefinatorgomyan@yahoo.com](mailto:adefinatorgomyan@yahoo.com)

nects the cementum of the tooth to the alveolar bone and provides anchorage through its oriented collagenous fiber bundles. The cells of the periodontal ligament preserve and repair the periodontal ligament as well as structures around it, such as neighboring alveolar bone and cementum. This ability to quickly remodel forms the basis of orthodontics [Franzoso G. et al., 1997; Beertsen W. et al., 2002]. The periodontal ligament contains cellular and non-cellular components. It comprises fibroblasts (43-55% of periodontal ligament connective tissue in rodents), vascular-related cells, nerve-related cells, inflammatory cells, undifferentiated mesenchyme cells, and the epithelial rests of Malassez. At the periphery of the periodontal ligament, cementoblasts and osteoblasts contour the hard tissue surfaces, and the osteoclasts may be present in areas of resorptive activity [Van Driel W. et al., 2000].

The fibroblast is an ordinary and functionally vital cell within the periodontal ligament. In health, fibroblasts control periodontal ligament tissue integrity and keep its homeostasis. It lies between collagen fibers and appears as compressed irregular disc ~30 micrometers in diameter. Fibroblasts contain high number of organelles and secrete collagen, elastin as well as glycosaminoglycans (GAGs) and glycoproteins. Fibroblasts are also capable of producing matrix degrading enzymes such as collagenase and metalloproteinases [Byers R., 1985; Byers R. et al., 1986; Arnoczky S. et al., 2004].

Cementoblasts produce the organic matrix of cementum. Their shape is connected to activity and when active they look like a distinct layer on the tooth root surface [Redlich M. et al., 2004 a; b].

The epithelial rests of Malassez within the periodontal ligament correspond to the remains of Hertwig's epithelial root sheath that can be histologically seen as strands of cells near the cementum surface. These rests, secrete enamel-like proteins onto the root surface and are closely packed cuboidal cells located nearer to the cementum than alveolar bone, stained deeply and are completely bordered by connective tissue cells. Epithelial rests are enclosed by an almost complete basal lamina. With age, the number of epithelial cells reportedly decreases. The function of these epithelial cells is unknown but it has been suggested that they may play an important role in the maintenance of homeostasis in tooth supporting structures. Epithelial cells might be also involved in repair cementogenesis and in the maintenance

of the periodontal ligament space [Maeda T., 1990; Ransjo M. et al., 1998].

Undifferentiated mesenchymal stem cells can be found within 5 micrometers of the blood vessels. Several studies have suggested that periodontal ligament stem cells play vital part in regeneration of periodontal defects [Nagatomo K. et al., 2006; Jo Y. et al., 2007].

Collagen fibers, which are set in bundles, together with small proportions of oxytalan and elastin fibers form the non-cellular fraction of the periodontal ligament. The collagen is aggregated into bundles of tough fiber groups orientated in specific planes, which can be identified histologically. The fiber bundles enlarge across the width of the periodontal ligament space, attaching to the cementum on the tooth side and inserting into the cribriform plate of the alveolar bone as Sharpey's fibers. Elastin is usually found connected with the blood vessels. Oxytalan fibers are distributed broadly in the periodontal ligament to form a network that surrounds the root and are associated with the neural elements. These fibers are thought to control vascular flow in relation to tooth function [Bloomfield S., 2001; Basaran G. et al., 2006].

The periodontal ligament is a greatly vascularized connective tissue. The vasculature in the periodontal ligament is adapted to resist high intermittent pressure during mastication. It also provides for substrate and metabolite exchange between blood and periodontal tissue, including dentine [Alhashimi N. et al., 2001; Casa M. et al., 2006].

The core blood supply of the ligament is derived from the superior and inferior alveolar arteries. These arteries are branches of the maxillary artery [Cahill D., 1969]. They course through the alveolar bone and give off branches that go through the cribriform plate of the alveolus to go into the periodontal space. The vessels course in an apical-occlusal way and have broad transverse connections and arteriovenous anastomoses. Venous drainage occurs in an apical course towards larger diameter venules. Lymphatic vessels drain correspondingly [Ajubi N. et al., 1999].

The nerve supply of the periodontal ligament is derived from the fifth cranial nerve, the trigeminal nerve, which emerges from the ventral surface of the pons, close to its upper border, as a large sensory and smaller motor root [Van Driel W. et al., 2000].

This provides the sensory supply to the face scalp, nasal mucosa, oral tissues, and the motor supply to

the muscles of mastication. The trigeminal nerve innervates the periodontal ligament from either its maxillary nerve or inferior alveolar nerve branches. Nerve fibers supplying the periodontal ligament pass through foraminae in the alveolar bone to go into the periodontal ligament space close to the tooth apex, while others enter through the lateral aspect of the alveolar wall. Nerve fibers and associated blood vessels run parallel to the long axis of the tooth. They are mainly found in the two thirds of the ligament space neighboring to the alveolar bone. Single myelinated and unmyelinated fibers have been observed near the avascular cementum area of the ligament [Kanzaki H. et al., 2002].

There is no complete confirmation concerning the presence of the parasympathetic nerve supply inside the periodontal ligament, while the postganglionic fibers of the sympathetic autonomic system arise from the superior cervical ganglion. The sensory innervation subserves touch, pressure and pain as well as proprioceptive function; though, the greater part of neurons also responds to mechanical stimulation. The cell bodies of these mechanoreceptors are located either in the trigeminal ganglion or in the mesencephalic trigeminal nucleus. Sensory neurons are usually classified physiologically according to their axonal conduction velocity and their adequate stimuli. Mechanoreceptors inside the periodontal ligament are expected to be the large diameter fibers [Franzoso G. et al., 1994; Fukushima H. et al., 2003], which respond to very low-threshold stimuli, such as forces applied to teeth and supporting structures. Small myelinated A5 fibers are slow conducting, are usually high-threshold mechanoreceptors, and respond to noxious stimuli. Unmyelinated C fibers form the mainstream of sensory neurons and they respond to noxious stimuli, plus to crude touch and temperature [Hannam A., 1982].

Four types of receptors are found in relationship with the periodontal ligament. These include: free nerve endings, Ruffini-like corpuscles, coiled endings and spindle-like endings. The free nerve endings have a tree-like configuration and are found throughout the length of the root, extending into the cementoblast layer. They begin from unmyelinated fibers; however, the terminal ends carry a Schwann cell envelope. These neuroreceptors are thought to function as nociceptors and mechanoreceptors. All nociceptors are free nerve endings. Nevertheless, not all free nerve endings are nociceptors since some

can respond to temperature and touch. Ruffini-like receptors are found mainly in the apical segment of the periodontal ligament. They have a dendritic appearance and are ensheathed in Schwann cells. The two patterns that may be distinguished are a simple form consisting of a single neurite and a complex form consisting of several terminations. These mechanoreceptors have finger-like processes that are anchored in the nearby collagen bundles that serve to increase the receptive field of the nerve terminals. The Ruffini-like terminals are able to monitor deformation of the neighboring collagen bundles, which leads to opening of the ion channels in the receptor membrane, consequently allowing ions to pass leading to depolarization of the receptor. A coiled form of receptor, whose function is unknown, is found in the middle section of the periodontal ligament. Spindle-like terminals bordered by a fibrous capsule are found close to the root apex. Oxytalan fibers in close association with blood vessels and nerves have been suggested to contribute to mechanoreception in the periodontal ligament [Lew K., 1989]. Tight relations of terminal nerve endings with the collagen bundles are indicative of collagen fibers belonging to mechanoreceptors as well that transmit to CNS the information about this bundles tension level and changing in teeth position during mastication [Harris R., 1975; Lew K., 1989; Mabuchi R. et al., 2002; Jonsdottir S. et al., 2006].

According to the research of T. Maeda (1990) and A. Ten Cate (1994) human periodontal ligament contains free nerve endings only. The latest appear as encapsulated corpuscles as well as lamellar and spindle shaped structures. Besides, these researchers revealed unmyelinated sympathetic nerve fibers, which form basket-like terminals around blood vessels in periodontal ligament [Ten Cate A., 1975; Maeda T., 1990].

It is essential to take into consideration the role of neuroregulatory mechanisms during the functional estimation of teeth periodontal ligament. Its basis is the estimation of the afferent nerve fibers functional condition.

According to findings, the periodontal ligament contains several nerve endings, which transmit information to CNS about degree of masticator forces and distribution in different parts of periodontal ligament [Mikheev V., Rubin L., 1954; Mayer G., 2001].

In this connection, the periodontal sensory receptors can be considered a barrier, which prevents teeth

**Table 1.**  
The characteristics of morphologically studied objects

	Men	Women
Number of investigated subjects	11	16
Age (years)	28 -39	25 -45
Number of blocks	16	24

and jaws overload and regulates masticator forces in combination with the temporo-mandibular articular receptors and proprioceptors of tendons and muscles [Mikheev V., Rubin L., 1954; Mayer G., 2001; Budilina S., 2002; Wise G. et al., 2004].

The aim of this study was to investigate peculiarities of nerve terminations and their distribution in periodontal ligament of different groups of human teeth, as well as the reaction of frontal teeth periodontal ligament sensory apparatus to restoration procedures using single and block prosthetic appliances. The study was done using “Periosensomer” device.

### MATERIAL AND METHODS

The mandible and maxillary fragments with teeth were material for morphological evaluation. These fragments were taken from people, who died accidentally after casual traumas. In total, we studied material from 27 persons (Table 1). We investigated 32 blocks, including both incisors and canine, as well as 8 blocks, including premolars and molars of mandible and maxilla from right and left sides. In total 40 blocks were studied.

The samples were taken during dissection in 6-12 hours after death, at various pathology departments of municipality hospitals of Moscow. The material

was fixed in 15-20% formalin solution for the period from 2.5 to 3 months. Bone structures were perforated for better fixation. Subsequent to fixation, the samples were decalcified in 25% Trilon B solution (pH 8.3-8.5). Then samples were washed using tap water and frozen. Frozen samples were sectioned in sagittal and frontal directions. For revealing the nerve fibers sections (30-70 mm in thickness) were treated with Ag salts by Bilshovski-Gross staining method in modification of L.I. Falin, as well as by Kampos’s method with subsequent hematoxylin staining. The nerve fibers myelin sheaths were revealed by staining with sudan black by Lizon’s method [Rubinov I., 1960].

For periodontal ligament sensory function evaluation, we used the “Periosensomer” device that was elaborated by us (Patent for the invention of the Russian Federation No. 2190983, valid from 20.11.2002) [Budylina S., 2002]. The investigation was done using elaborated methods, i.e. the food “holding” and “splitting” test (The Patent for the invention of the Russian Federation. No.2190983, valid from 20.11.2002) (Figure 1).

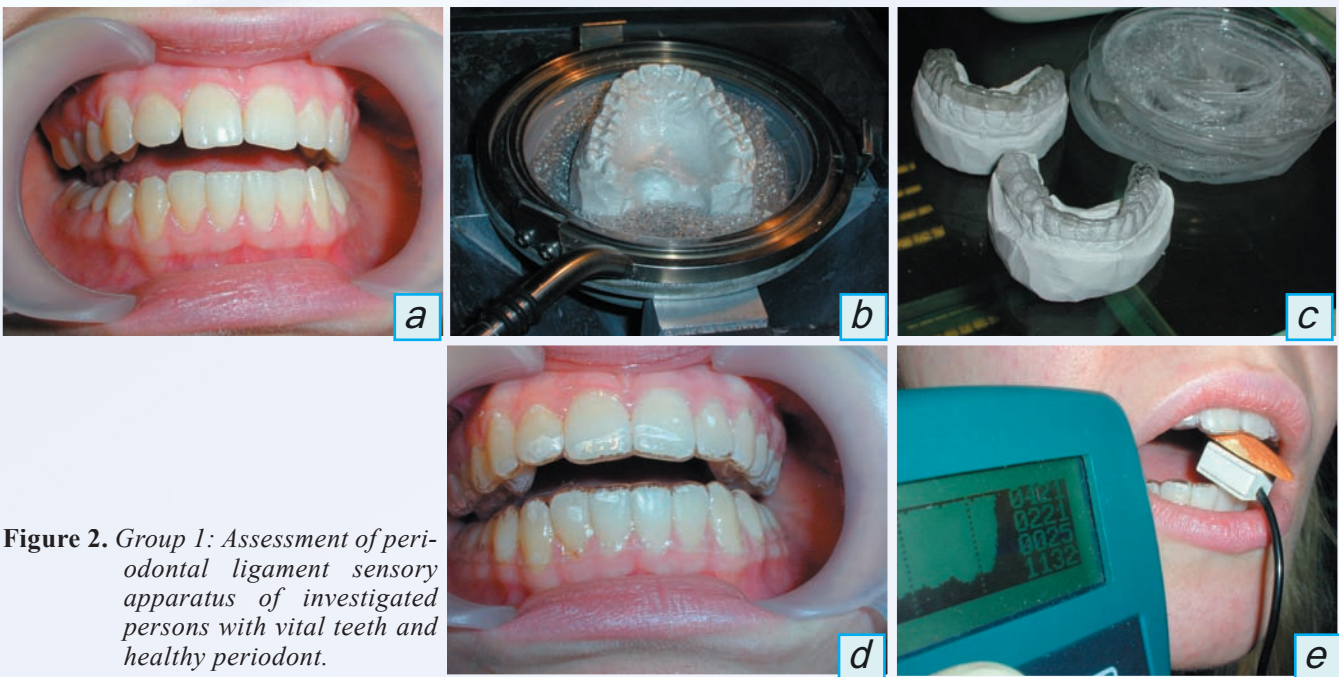
The research method consisted in estimation of masticatory pressure and dynamics of its change in the process of food holding and its splitting between antagonist frontal teeth at various stages of prosthetic treatment. In clinical conditions, 44 persons with orthognatic occlusion and a healthy periodont were investigated (Figure 2 e). These patients did not have any prosthetic or orthodontic appliances. Investigated patients were divided into 3 groups (Table 2).

Group 1: 18 patients (18 to 35 years old) had vital teeth and healthy periodont (Figure 2 a; d). This study was conducted before and after the temporary bridges were superimposed (Figure 2 b; c).

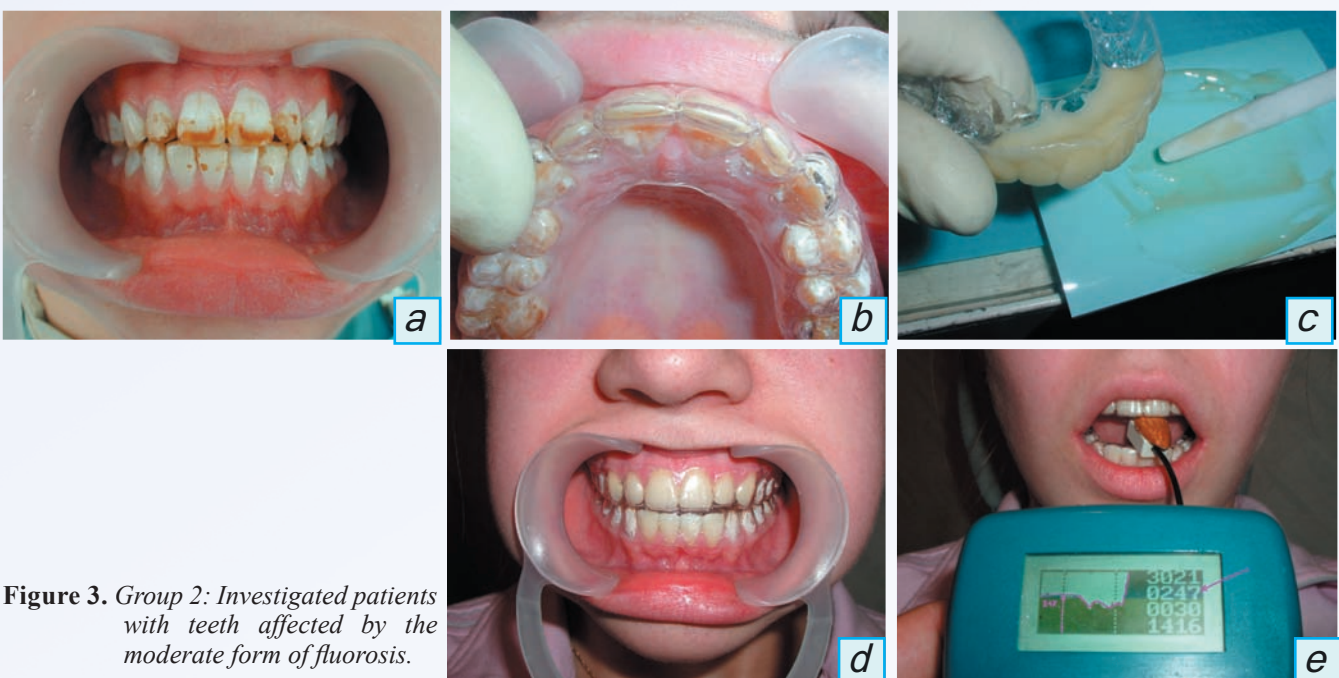


**Figure 1.**  
The “Periosensomer” device and Patent for the invention of the Russian Federation No.2190983, valid from 20.11.2002.

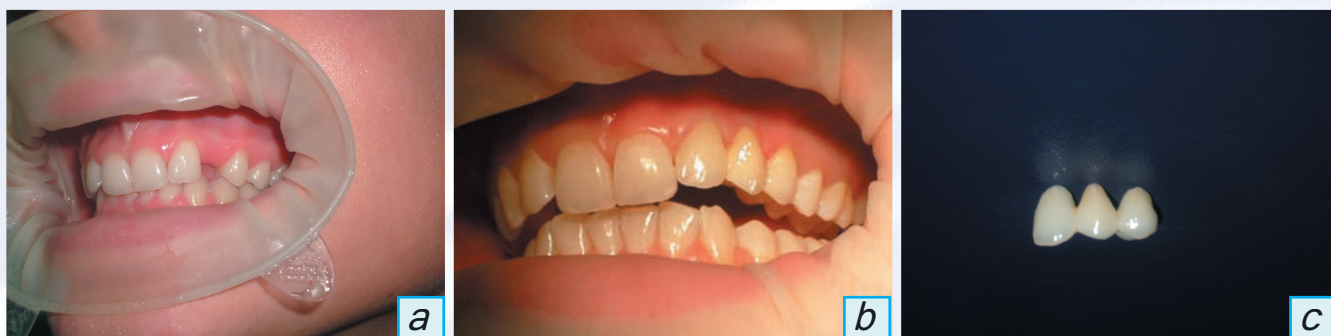		Table 2.		
		Main characteristics of investigated patents		
Group		Group 1 (with temporary bridges)	Group 2 (with venires)	Group 3 (with bridges)
Number of investigated patients:		18	12	4
Sex	Men:	12	3	2
	Women:	6	9	2
Age (years)		26.4 (8.6)	23.6 (6.4)	32.5 (7.5)



**Figure 2.** Group 1: Assessment of peri-odontal ligament sensory apparatus of investigated persons with vital teeth and healthy periodont.



**Figure 3.** Group 2: Investigated patients with teeth affected by the moderate form of fluorosis.



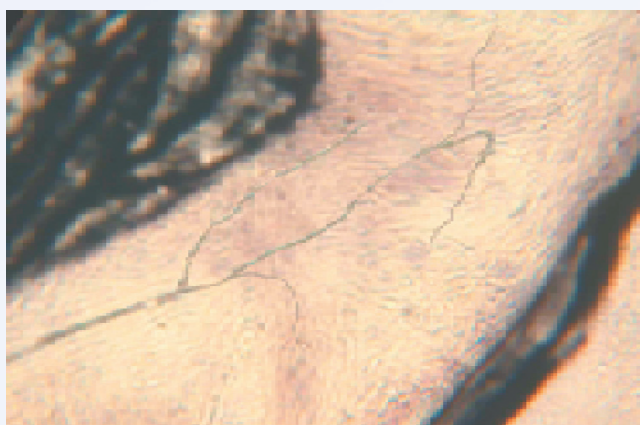**Figure 4.** Group 3: Investigated patients with vital teeth and healthy periodont, with the included defect (loss of 1 tooth) in frontal division of the upper jaw.

Group 2: 12 patients (18 to 30 years old) had healthy parodont and teeth affected with moderate form of fluorosis (Figure 3 a; d; e). The study was conducted before and after the anesthesia, as well as after fixation of temporary bridges united in blocks and after fixation of IPS-EMAX venires (IVOCLAR VIVADENT, Russia) (Figure 3 b; c).

Group 3: 4 patients (25 to 40 years old) had vital teeth and healthy periodont, with the included defect (loss of 1 tooth) in frontal division of the upper jaw. The study was conducted before and after anesthesia, after fixation of temporary bridges and after fixation of all ceramic bridges of IPS-EMAX prosthetic system (IVOCLAR VIVADENT, Russia) (Figure 4 a; b c).

### RESULTS

The morphological research of the teeth periodontal ligament apparatus revealed that it contains several receptors. All receptors of human periodontal ligament belong to the group of free nerve endings. The greater part of them has coiled or tree-like shape. The last ones can be simple or compound-branched.



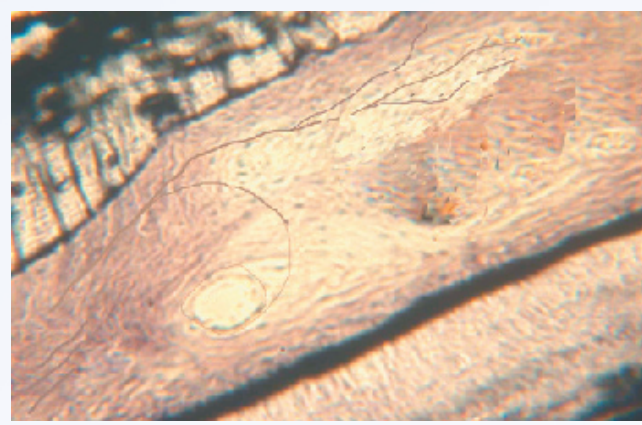
**Figure 5.** The simple tree-like nerve endings in incisor's lateral surface. Ag staining. 10x40.

The simple tree-like nerve endings are characterized by 3-4 terminals, which end on bundles of collagen fibers in periodontal ligament very close to each other (Figure 5).

The compound branched tree-like nerve endings had completely different appearance. In this case the nerve trunk gave off side branches, which penetrated collagen fibers continuing branching and terminated amongst them. These branches were found in different planes and occupied significant part of periodontal ligament.

In both cases we revealed tree-like nerve endings, which were partly connected to the collagen bundles of periodontal ligament, partly established contact with blood vessels found in area of their branching, therefore forming polyvalent (vessel-tissue) receptors (Figure 6).

The coiled nerve endings form separate group of periodontal ligament nerve terminations. Coiled nerve endings are found in a small area. Usually they are set perpendicular to the periodontal ligament collagen bundles as well as in layers of loose connective tissue. In contrast to tree-like nerve



**Figure 6.** The tree-like nerve fiber in canine periodontal ligament, nerve terminations have contact with the wall of blood vessel. Ag staining. 10x40.

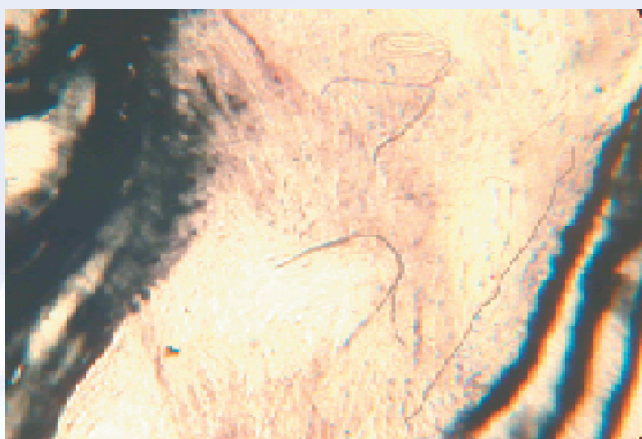


Figure 7. The double coiled nerve endings in incisor's periodontal ligament. Ag staining. 10x40.

endings, they do not brunch, so they occupy smaller areas than tree-like nerve fibers. In parallel with single coiled nerve terminations in periodontal ligament the double ones are found, when nerve fiber divides into two brunches and each of them becomes coiled (Figure 7). Another difference between tree-like and coiled nerve endings is their location. Tree-like nerve endings are found in neck and at the lateral apical regions of periodontal ligament. The coiled nerve terminations are present predominantly in the apical part.

With regard to distribution of nerve endings in various areas of periodont it should be noted that the apical part of periodontal ligament has the richest innervations and the neck region – the least. Tree-like nerve endings with many brunches predominate in lateral parts of periodontal ligament. Interestingly, their brunches are arranged in across the periodontal space. We did not find any nerve terminations in close relation to root cementum.

The comparative analysis regarding distribution of nerve endings in periodont of different group teeth showed that incisors have more developed nerve endings than molars. The tree-like nerve terminations are found mainly in molars.

We did not determine any difference at nerve fibers distribution in men and women.

The investigation of periodontal ligament apparatus sensory function revealed that patients with healthy periodontal ligament (Group 1) need certain position of both maxilla and mandible for food holding, which further will provide food splitting.

We recorded weak efforts during 3 sec, the strength of which was within the limits of 1 N. The intensity of pressure force was recorded in Neutons (N). It is visible from the diagram of “Periosen-

somer” device as a curve with small amplitude fluctuations. In this case food splitting takes place rapidly with force increasing up to 18 N and abrupt decrease at the end of test (Figure 8).

After thin transparent prostheses (0.5 mm in thickness) had been fixated on maxillary vital teeth the amplitude of curves increased up to 3 N during the holding phase and abruptly increased and fell during splitting phase. In fact, food was not split but crushed (Figure 9).

After anesthesia in patients of Groups 2 and 3, the force necessary for food holding was about 3-4 N (Figure 10).

In this case, curves amplitude was equal to 1-2 N. Food holding phase was longer than in Group 1, because of prolonged search for optimal jaw position necessary for food splitting. The splitting phase usually resulted in food squeezing though; “Periosensomer” device registered maximal forces equal to 18 N. Almost all patients pointed out that they were not sure in correct jaw position necessary for food splitting (Figure 3).

The objective and subjective indices appearing after anesthesia can be explained by loss of periodontal ligament sensitivity. Upon anesthesia, afferent nerve impulses from periodontal receptors are significantly changed which leads to mastication initial stage control failure, i.e. food holding and splitting phase's failure.

In Group 2 patients after fixation of temporary block appliances we revealed decrease of sensory function and increase of holding force up to 4 N (Figure 11).

The fixation of permanent single venire leads to the sensory function restoration, which becomes equal to 1 N, analogous to that before anesthesia (Figure 12).

In patients of Group 3 the decrease of sensory function was recorded after fixation of temporary block dentures (Figure 13), as well as after fixation of permanent bridges (Figure 14). In both cases, holding force was equal to 3-4 N.

## DISCUSSION

Thus, the results of our research allow us to conclude that periodontal ligament of the tooth has well developed, compound sensory apparatus.

On the basis of morphological studies differences in the distribution of nerve endings of various types of teeth were identified. The healthy periodontal

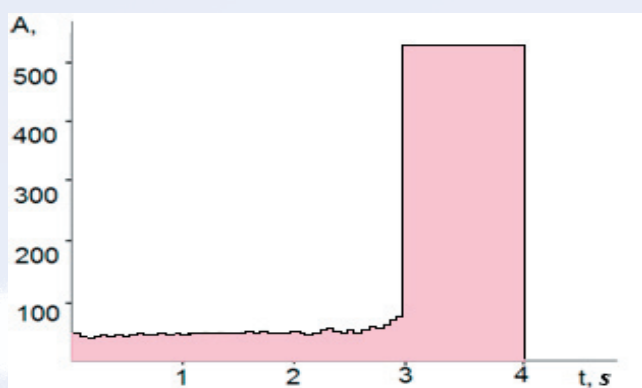


Figure 8. Group 1 (Control).

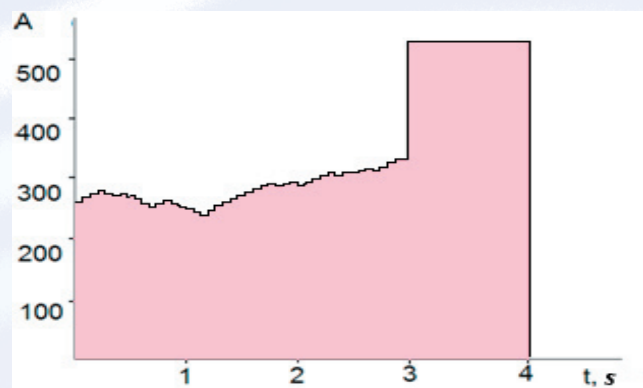


Figure 9. Group 2 (transparent temporary prostheses.)

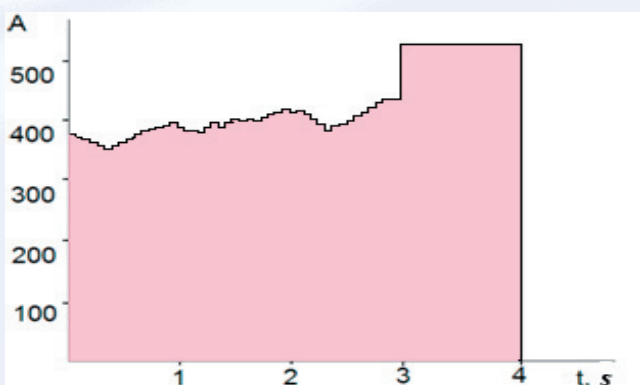


Figure 10. Groups 2 and 3 (anesthesia).

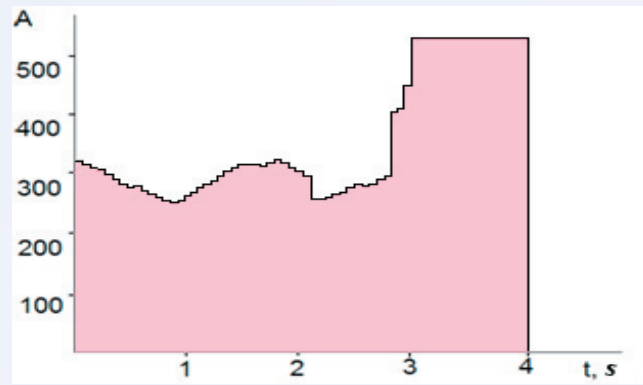


Figure 11. Group 2 (temporary prostheses)

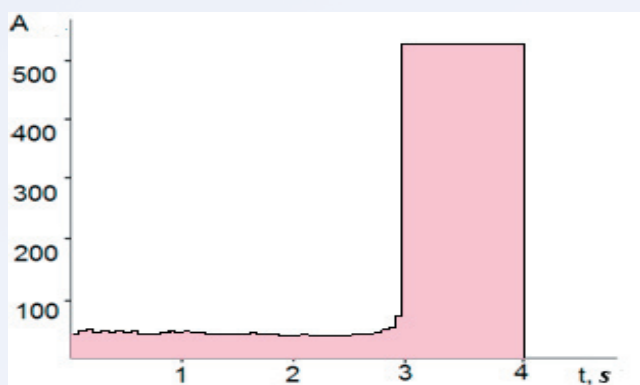


Figure 12. Group 2 (IPS venire- EMAX).

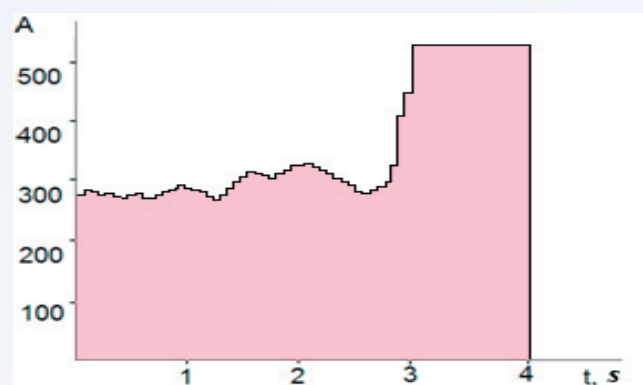


Figure 13. Group 3: Temporary prostheses.

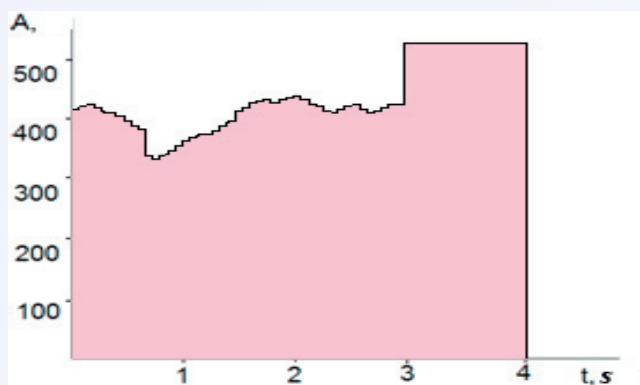


Figure 14. Group 3: permanent all ceramic bridges IPS-EMAX

ligament of frontal teeth contains a variety of nerve endings. The periodontal ligament of incisors and canines contains more nerve terminations than the periodontal ligament of molars and premolars.

The following fact is of interest: distribution of nerve endings in the periodontal ligament is uneven. Numerous nerve fibers are found in apical part of periodontal ligament. They are less frequent at the upper 1/3 part of root periodontal ligament and almost absent in tooth circular ligament.

The investigation on functional condition of periodontal ligament sensory apparatus revealed that

Table 3.

Results of the research: evaluation of the periodontal ligament sensory function

Study Groups	Before anesthesia (N)	After anesthesia (N)	After the temporary appliances fixation (N)	After the permanent dentures fixation (N)
Group 1	1	-	3	-
Group 2	1	3	4	1
Group 3	1	3	4	4

during food holding phase the least forces are recorded, when the jaw finds optimal position. At food holding by antagonist teeth testing of food position and consistence takes place. The changes in jaw position are provided by sensitivity of frontal teeth periodontal ligament receptors.

The patients with healthy periodontal ligament and single appliances have normal (up to 1 N) receptors sensitivity. In this case, the full value of food holding and splitting is recorded. The usage of block dentures leads to changes of sensitivity threshold. Patients with block dentures do not feel food and its position normally, because of changing periodontal ligament sensitivity. They apply high forces for food splitting. Possibly, it is related to disturbance of periodontal ligament sensory function (small particles catching). In this case, afferent impulses bring to CNS information, which does not correspond to the real quality of food. CNS non-coordinated reaction leads to not adequate response of masticator muscles and distribution of forces.

We established that during certain stages of prosthetic treatment, such as anesthesia and fixation of temporary bridges connected in one block, the sensory function of periodontal ligament decreased up to 3-4 times. It can be either restored after fixing permanent single prosthetic appliances (e.g. venires) or remain decreased after fixing permanent bridges.

Our study concluded: in case of block prosthetic appliances usage, the suppression of periodontal ligament sensory function leads to the incensement of masticatory forces, which results in the stress of teeth included in block, as well as antagonists. Estimating periodontal ligament sensory function and sensory reaction dynamics can be introduced as a method for functional diagnostics in prosthetic dentistry.

Data obtained from the patients with fixed prostheses are of no less interest. In particular, it is revealed that upon prosthetic rehabilitation of included defects using block prostheses with several units, there is a sharp decrease of threshold values of tactile sensitivity that is expressed on the device in the form of increase of digital indicators at "holding" phase by dozens units. In addition, it was revealed that changes of sensitivity threshold depend also on the number of teeth included in the block prosthetic construction. The more teeth in an orthopedic construction, the further their sensitivity is decreased, i.e. there is a higher initial threshold load. These indicators in a distant terms (from 12 months to 2 years) partially decrease, i.e. there is an adaptation to the prosthetic rehabilitation [Falin L., 1963]. On the other hand, there is also reorganization in certain groups of chewing muscles. These changes are expressed in the form of increase in the size of muscular fibers and their hypertrophy, change of indicators of their bioelectric activity, change of potential of action and resting potentials, which are in detail described in V.N. Kopejkin's publications [Kopejkin V., 1988].

It is necessary to take into consideration that nervous terminations are closely connected with bunches of collagen fibers of periodontal ligament forming an original sensory apparatus, which reacts to the changes of pressure in collagen fibers.

It gives the ground to consider that this apparatus plays rather important role in the chewing act being connected right after touch of the food object to the teeth. Signals going from receptors allow to precisely dose out masticatory forces and force of muscular reductions. Simultaneously, alongside with it, the jaw finds optimal position necessary for optimum processing of food.

## REFERENCES

1. Adachi T., Sato K., Tomita Y. Directional dependence of osteoblastic calcium response to mechanical stimuli. *Biomech Model Mechanobiol* 2003; 2: 73-82.
2. Ajubi N.E., Klein-Nulend J., Alblas M.J., Burger E.H., Nijweide P.J. Signal transduction pathways involved in fluid flow-induced PGE2 production by cultured osteocytes. *Am. J. Physiol.* 1999; 276: 171-178.
3. Alhashimi N., Frithiof L., Brudvik P., Bakhtiet M. Orthodontic tooth movement and de novo synthesis of proinflammatory cytokines. *Am. J. Orthod. Dentofacial Orthop* 2001; 119: 307-312.
4. Arnoczky S.P., Tian T., Lavagnino M., Gardner K. Ex vivo static tensile loading inhibits MMP-1 expression in rat tail tendon cells through a cytoskeletonally based mechanotransduction mechanism. *J. Orthop. Res.* 2004; 22: 328-333.
5. Basaran G., Ozer T., Kaya F.A., Hamamci O. Interleukins 2, 6, and 8 levels in human gingival sulcus during orthodontic treatment. *Am. J. Orthod. Dentofacial Orthop.* 2006; 130: e1-6.
6. Beertsen W., Holmbeck K., Niehof A., Bianco P., Chrysovergis K., Birkedal-Hansen H. et al. On the role of MT1-MMP, a matrix metalloproteinase essential to collagen remodeling, in murine molar eruption and root growth. *Eur. J. Oral Sci.* 2002; 110: 445-451.
7. Bloomfield S.A. Cellular and molecular mechanisms for the bone response to mechanical loading. *Int. J. Sport Nutr. Exerc. Metab.* 2001; 11: 128-136.
8. Budylina S.M. [The maxillofacial region sensory function] [published in Russian]. *Russian dentistry journal.* 2002; 4: 4-9.
9. Byers R.M. Sensory innervation of periodontal ligament of rat molars of unencapsulated Ruffini-like mechanoreceptors and free nerve endings. *J. Comp. Neurol.* 1985; 231: 500-518.
10. Byers R.M., O'Connor T.A., Martin T.F., Dong W.K. Mesencephalic trigeminal sensory neurons, axon pathways and structure of mechanoreceptive endings in periodontal ligament. *J. Comp. Neurol.* 1986; 250: 181-191.
11. Cahill D.R. The histology and rate of tooth eruption with and without temporary impaction in the dog. *Anat. Rec.* 1969; 166: 225-238.
12. Casa M.A., Faltin R.M., Faltin K., Arana-Chavez V.E. Root resorption on torqued human premolars shown by tartrate-resistant acid phosphatase histochemistry and transmission electron microscopy. *Angle Orthod.* 2006; 76: 1015-1021.
13. Cho M.I. Periodontal ligament and cementum. *Afr. Dent. Res.* 1995; 1(Suppl.): 17-25.
14. Crotti T., Smith M.D., Hirsch R., Soukoulis S., Weedon H., Capone M. et al. Receptor activator NF kappaB ligand (RANKL) and osteoprotegerin (OPG) protein expression in periodontitis. *J. Periodontal Res.* 2003; 38: 380-387.
15. Falin L.I. [The oral cavity and teeth histology and embryology][published in Russian]. Moscow 1963. P. 121-131; 140-146.
16. Franzoso G., Carlson L., Xing L., Poljak L., Shores E.W., Brown K.D., et al. Requirement for NF-kappaB in osteoclast and B-cell development. *Genes Dev.* 1997; 11: 3482-3496.
17. Fukushima H., Kajiyama H., Takada K., Okamoto F., Okabe K. Expression and role of RANKL in periodontal ligament cells during physiological root-resorption in human deciduous teeth. *Eur. J. Oral Sci.* 2003; 111: 346-352.
18. Hannam A.G. The innervation of the periodontal ligament. In: "The periodontal ligament in health and disease". Ed. by B.K.B. Berkovitz, B.J. Moxham and H.N. Newman. Pergamon Press, Oxford. 1982. P. 173-196.
19. Harris R. Innervation of human periodontium. *Monographs in Oral Sciences.* 1975; 4: 27-46.
20. Jo Y.Y., Lee H.J., Kook S.Y., Choung H.W., Park J.Y., Chung J.H. et al. Isolation and characterization of postnatal stem cells from human dental tissues. *Tissue Eng.* 2007; 13: 767-773.
21. Jonsdottir S.H., Giesen E.B., Maltha J.C. Biomechanical behaviour of the periodontal ligament of the beagle dog during the first 5 hours of orthodontic force application. *Eur. J. Orthod.* 2006; 28: 547-552.

22. Kanzaki H., Chiba M., Shimizu Y., Mitani H. Periodontal ligament cells under mechanical stress induce osteoclastogenesis by receptor activator of nuclear factor kappaB ligand up-regulation via prostaglandin E2 synthesis. *J. Bone Miner. Res.* 2002; 17: 210-220.
23. Kanzaki H., Chiba M., Takahashi I., Haruyama N., Nishimura M., Mitani H. Local OPG gene transfer to periodontal tissue inhibits orthodontic tooth movement. *J. Dent. Res.* 2004; 83: 920-925.
24. Kopejkin V.N. [Methods of clinical examination of patients and general symptomatology of tooth-and-jaw diseases][published in Russian]. *Prostodontics dentistry*. Moscow. Medicine Publishers. 1988. P. 94-99
25. Lew K.K. Orthodontically induced microvascular injuries in the tension zone of the periodontal ligament. *J. Nihon Univ. Sch. Dent.* 1989; 31: 493-501.
26. Mabuchi R., Matsuzaka K., Shimono M. Cell proliferation and cell death in periodontal ligaments during orthodontic tooth movement. *J. Periodontal Res.* 2002; 37: 118-124.
27. Maeda T. Sensory innervation of the periodontal ligament in the incisor and molar of the monkey, *Macaca fuscata*. An immunohistochemical study for neurofilament protein and glia-specific S-100 protein. *Arc. histol. Jap., Niigata.* 1990; 50: 437-454.
28. Mayer G. [Practicing dentist's collaboration with the other specialization physicians: actual aspects in temporo-mandibular junction functional diagnostics and treatment] [published in Russian]. *Prostodontics Panorama.* 2001; 3: 2-4.
29. Mikheev V.V., Rubin L.R. [Dental neurology][published in Russian]. *Medgiz.* 1954; 3: 50.
30. Nagatomo K., Komaki M., Sekiya I., Sakaguchi Y., Noguchi K., Oda S. et al. Stem cell properties of human periodontal ligament cells. *J. Periodontal Res.* 2006; 41: 303-310.
31. Ransjo M., Marklund M., Persson M., Lerner U.H. Synergistic interactions of bradykinin, thrombin, interleukin 1 and tumor necrosis factor on prostanoïd biosynthesis in human periodontal-ligament cells. *Arch. Oral Biol.* 1998; 43: 253-260.
32. Redlich M., Asher Roos H., Reichenberg E., Zaks B., Grosskop A., Bar Kana I. et al. The effect of centrifugal force on mRNA levels of collagenase, collagen type-I, tissue inhibitors of metalloproteinases and beta-actin in cultured human periodontal ligament fibroblasts. *J. Periodontal Res.* 2004 a; 39: 27-32.
33. Redlich M., Asher Roos H., Reichenberg E., Zaks B., Mussig D., Baumert U. et al. Expression of tropoelastin in human periodontal ligament fibroblasts after simulation of orthodontic force. *Arch. Oral Biol.* 2004 b; 49:119-124.
34. Rubinov I.S. [The role of neural reception in teeth strength at paradontosis][published in Russian]. Moscow. Medicine Publishers. 1960. P. 23-26.
35. Ten Cate A.R. The dentogingival junction: an interpretation of literature. *J. Periodontology.* 1975; 46: 475-482.
36. Van Driel W.D., van Leeuwen E.J., Von den Hoff J.W., Maltha J.C., Kuijpers-Jagtman A.M. Time-dependent mechanical behaviour of the periodontal ligament. *Proc. Inst. Mech. Eng. [H]* 2000; 214: 497-504.
37. Wise G.E., Ding D., Yao S. Regulation of secretion of osteoprotegerin in rat dental follicle cells. *Eur. J. Oral Sci.* 2004; 112: 439-444.
38. Zhulev E.N. [Fixed dentures][published in Russian]. 1998. Moscow. 43-45.